



CASE STUDY DETAILS

PATIENT NAME: Reggie WEIGHT: 52 lbs
 AGE/SEX: 12 y / Male BREED: Retired Working Border Collie
 CONDITION: Periodontal disease with horizontal and vertical bone loss.
 TREATMENT: Stimulation of bone growth with **Osteoallograft™ Periomix™**
 SURGEON: Judith E. Yee, DVM, Diplomate AVDC
 Dept of Dentistry and Oral Surgery
 Desert Veterinary Specialists
 Palm Desert, CA
 TYPE OF GRAFT USED:
 • **Osteoallograft™ Periomix™**

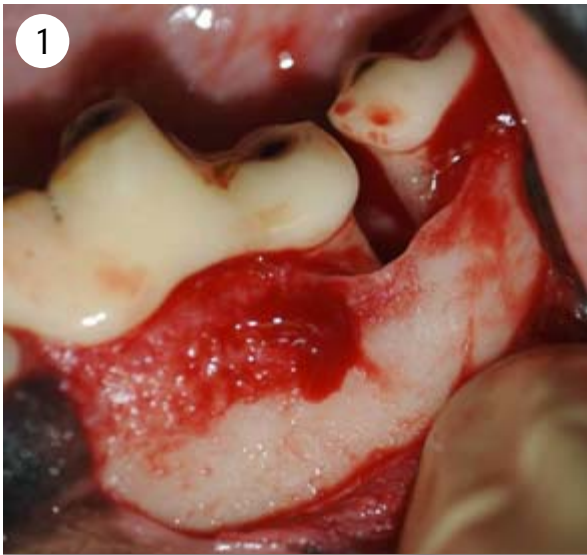


Figure 1: Surgical flap is created. Perio-dontal disease caused a marked degree of bone loss that generally requires extraction.

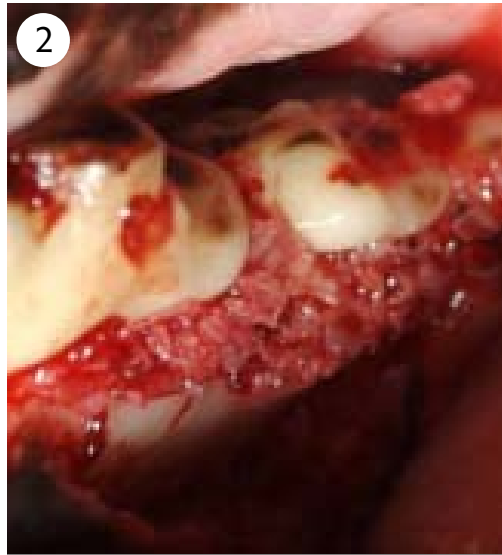

Figure 2: Mixed with patient blood, the **Osteoallograft™ Periomix™** forms a granular paste that conforms well to the surgical site.



Figure 3: **Osteoallograft™ Periomix™**

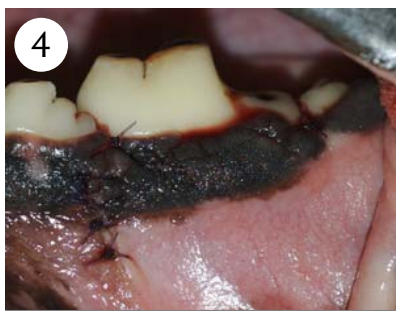


Figure 4: Surgical flap is sutured closed.

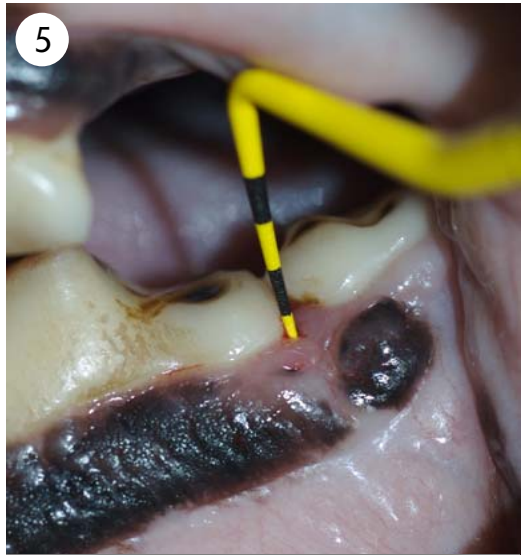
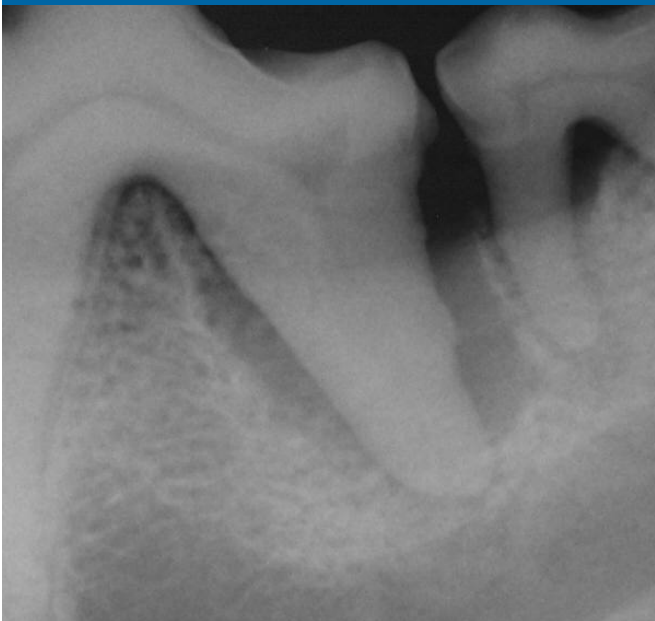
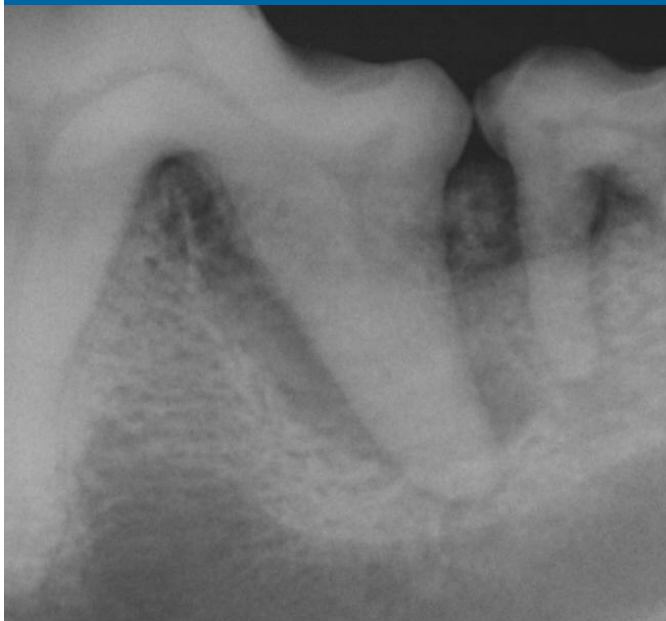
Figure 5: Follow-up at 8 weeks. Reconstruction of periodontium to 2 mm probing depth has occurred and extraction has been avoided.

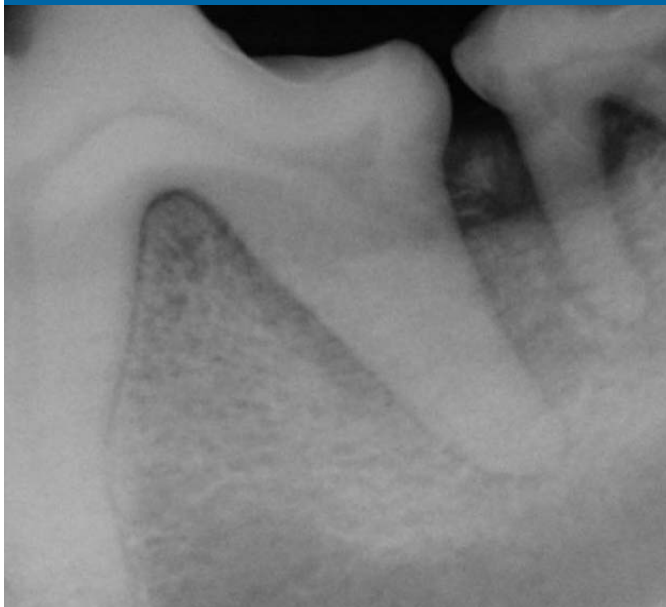PRE - OP



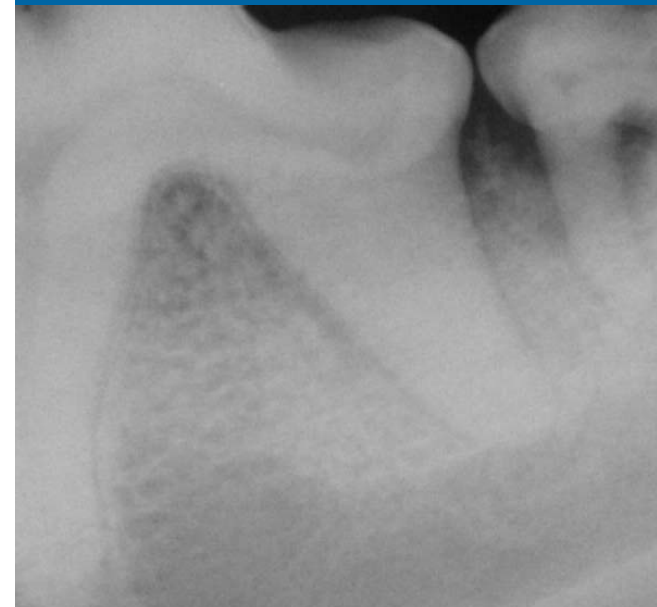IMMEDIATE POST - OP



FOLLOW - UP AT 4 WEEKS



FOLLOW - UP AT 8 WEEKS



PATIENT NAME: Reggie WEIGHT: 52 lbs
AGE/SEX: 12 y / Male BREED: Retired Working Border Collie

Bone graft for this case study provided by Veterinary Transplant Services, Inc. For more information about bone grafts, please call VTS at 1-800-558-5223 or visit us at www.vtsonline.com.

