

## GEM Vet™ (PDGF Enhanced Bone Graft) & VTS Radius Section

Abe, a ranch dog, was diagnosed with an osteosarcoma that required removal of a large portion of his mandible followed by 5 rounds of chemotherapy.

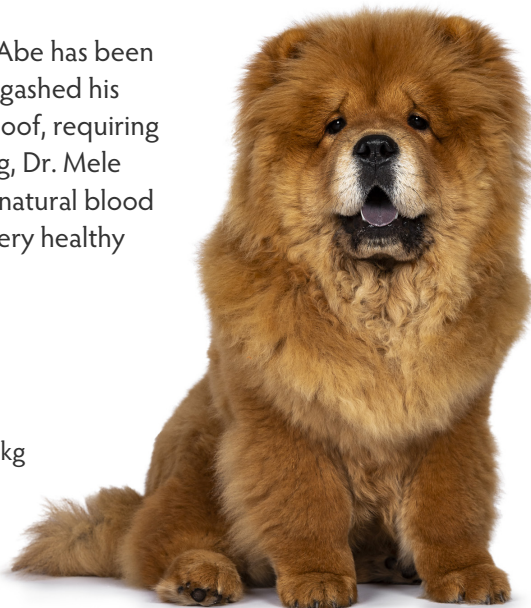
Prior to surgery, Dr. Rocco Mele consulted with Dr. Helen Newman from VTS on what might be helpful in healing the defect. Dr. Mele removed 7cm of mandible and replaced it with a section of VTS surface demineralized radius coated with GEM Vet which was wrapped in a collagen membrane.

**FOUR MONTHS LATER:** Abe has been doing great, however, he gashed his gingiva by chewing on a hoof, requiring sutures to close. At closing, Dr. Mele noted his mandible has a natural blood supply, and the tissue is very healthy and solid over the graft.

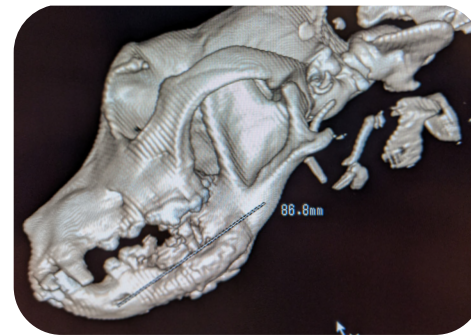### ABE

12 year-old, Chow mix, 32.7 kg

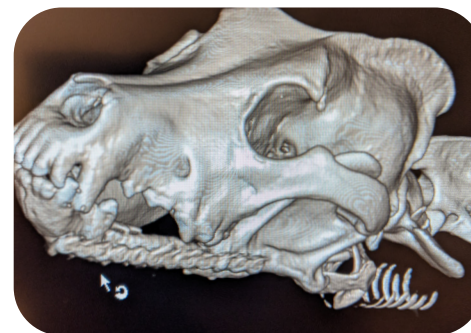Segmental allograft after mandibulectomy



PRE-OP

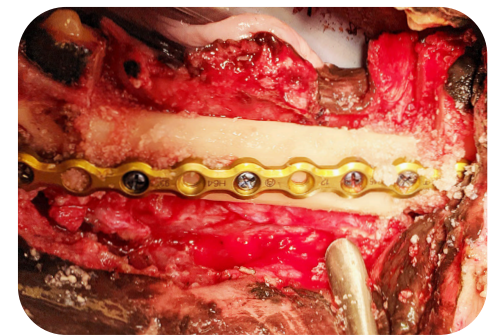
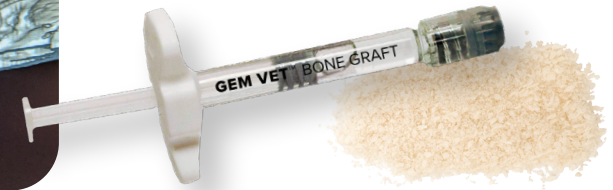
PRE-OP

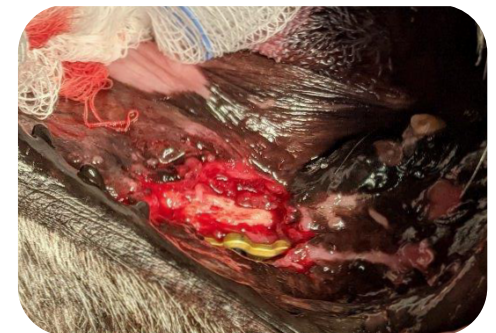

4 MONTH POST-OP

Harnessing the power of rhPDGF & allograft



INTRA-OP



4 MONTH POST-OP