

GEM Vet™ PDGF-Enhanced bone graft: accelerating the healing process

Gus sustained a humeral fracture while playing. Despite failure of the plated repair a month after surgery, the owners declined revision surgery and opted for symptomatic treatment with regular splint and bandage.

Five months later, radiographs still showed no evidence of healing so the owners finally agreed to have revisional surgery using a plate, K-wires, and GEM Vet was packed into the fracture site.

Six weeks after replating with GEM Vet the humeral fracture was finally fused.

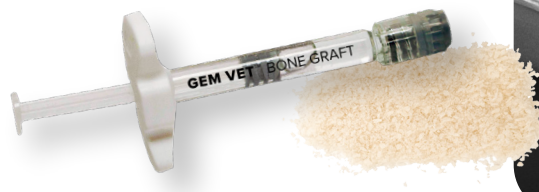

GUS

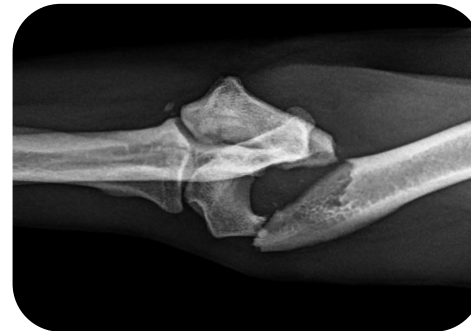
1 year-old

Cavalier King Charles Spaniel

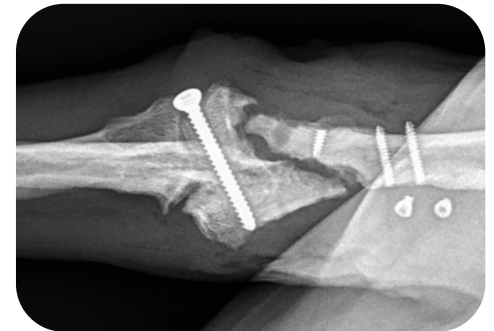
Revisional surgery for
Left Humeral Fracture



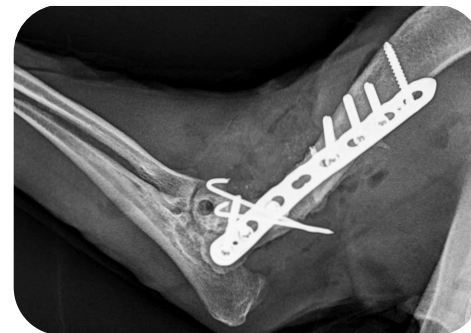
Harnessing the power of rhPDGF & allograft



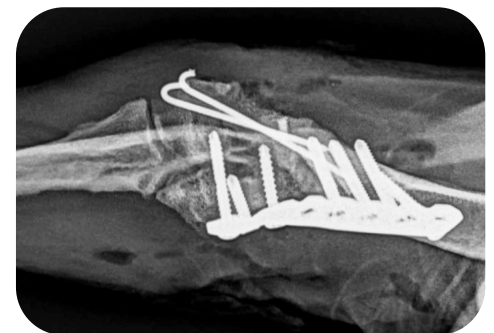PRE-OP



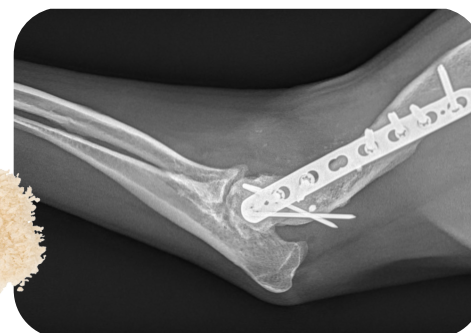PRE-OP



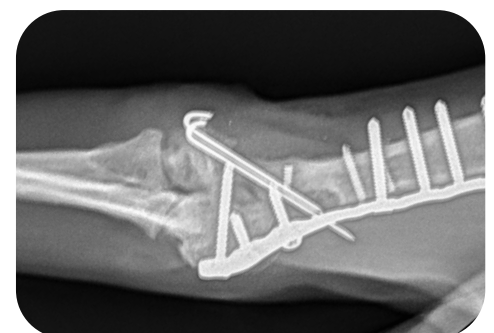IMMEDIATE POST-OP



IMMEDIATE POST-OP



6 WEEKS POST-OP



6 WEEKS POST-OP