

OSTEOALLOGRAFT™ PERIOMIX™

Saving teeth instead of extracting

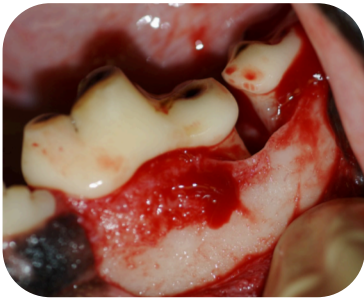Reggie, a retired working Border Collie, presented with severe vertical and horizontal bone loss.

The site of bone loss was packed with Periomix. Periomix provides the optimal environment to stimulate reconstruction of periodontium and restoration of lost bone.

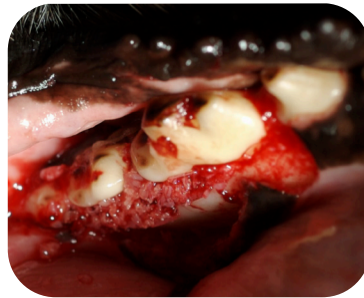
Brushing was maintained for the initial 8 week period; in spite of limited brushing, Reggie's teeth were preserved and periodontal disease was prevented for the long term.

REGGIE

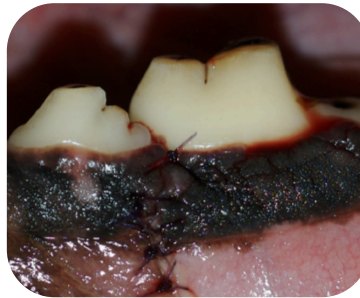
12 year-old Border Collie
52 lbs.



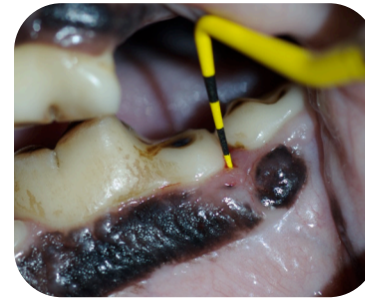After cleaning and root planing



Pack PeriomiX

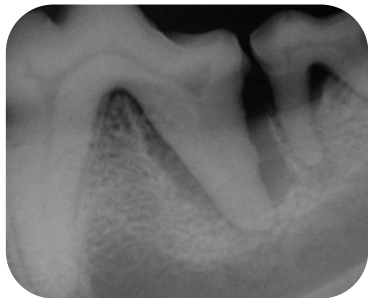


Surgical flap is sutured closed

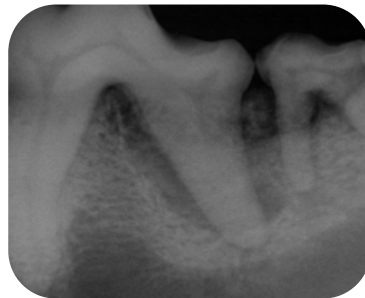


8 Weeks Post-Op

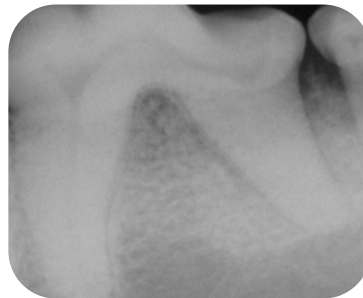8 Weeks Later



Pre-Op

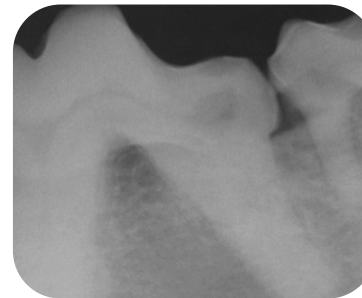

Immediate Post-Op



Bone height restored.

32 Months Later



Alveolar ridge height maintained long-term.

