



# Allograft Tendons

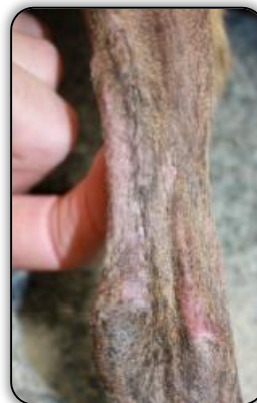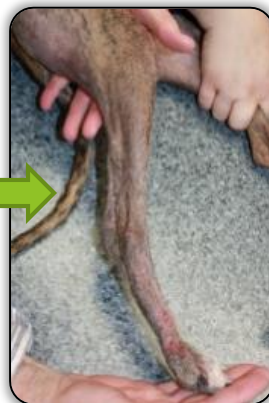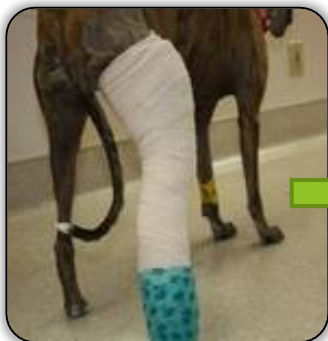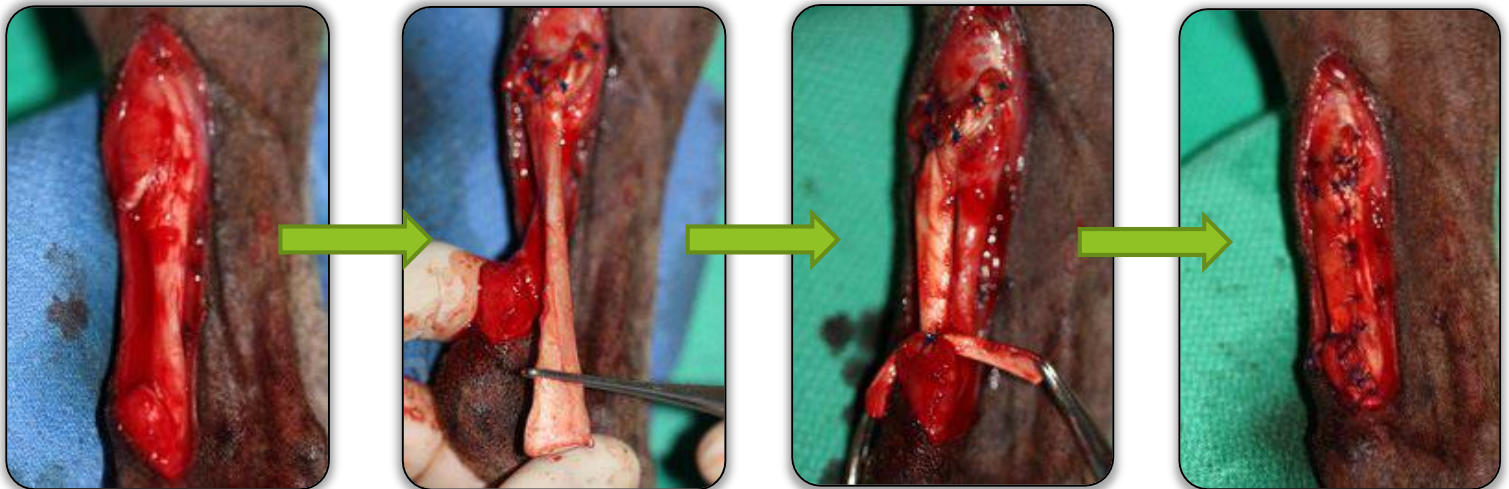
## Heal Devo's Ruptured Achilles



### Treatment of ruptured Achilles tendon in a canine

Devo was referred for an injury to his right hind limb. Prior to referral, Devo was placed on exercise restriction and a medication regimen, however his limp did not improve. Devo was found to have a severed Achilles and SDF (superficial digital flexor) tendon.

An **SDF allograft** tendon from VTS was used to repair the tendon. The allograft tendon is sutured to the fully debrided severed end of the tendons. The allograft is pulled tight to ensure that it is the approximate length of the injured tendon and secured distally around the calcaneus.



After protecting the grafted site with a padded splint, **Devo fully recovered and returned to his active lifestyle.**

**Devo is now 5 years from his initial surgery, and still has a fully-functional hock!**



**VTS offers a wide selection of soft tissue allografts for a range of applications!** Whatever your clinical need, we are ready to work with you to find the perfect allograft, to help ensure positive clinical outcomes in **every case, every surgery.**