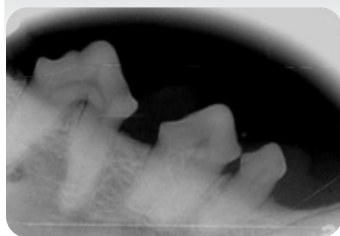
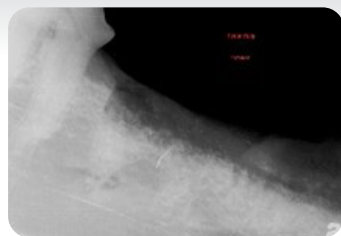

## FUSION™

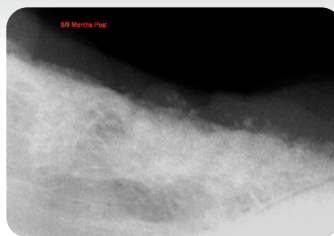
### NUGGET 8.5 Year Old Golden Retriever



PRE-OP



IMMEDIATE POST-OP



8 MONTH FOLLOW UP

#### FUSION

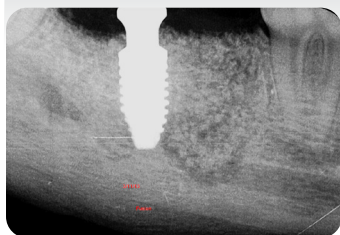
##### DX & PROCEDURE:

Biopsy of severe extensive gingival hyperplasia showed marked multifocal to coalescing lymphoplasmacytic gingivitis requiring extraction and alveolar ridge reduction. Extraction sites filled with VTS FUSION.

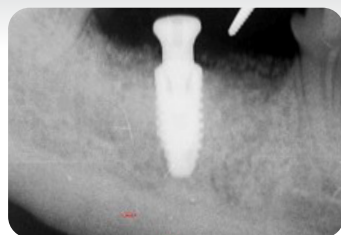##### OBSERVATION:

Good bone maintenance. Solid alveolar margin and normal anatomy without further bone loss.

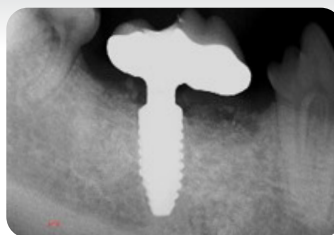### MAC 4.5 Year Old Rottweiler Mix



IMMEDIATE POST-OP



2 MONTH FOLLOW UP



4 MONTH FOLLOW UP

#### FUSION

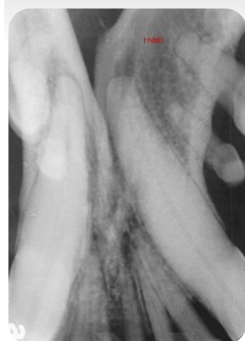
##### DX & PROCEDURE:

Periapical bone loss (abscess). Extraction with immediate placement in furcation bone surrounded by VTS FUSION.

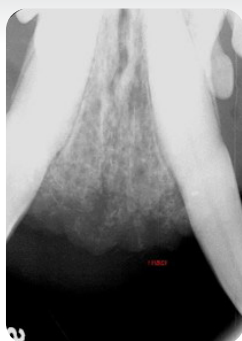##### OBSERVATION:

Very nice remodeling of the FUSION over 2 mos. Minimal bone loss with maintenance of alveolar crest at both follow up intervals.

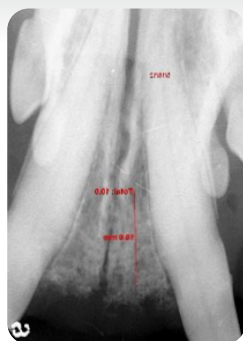### WALLY 5 Year Old Finnish Spitz



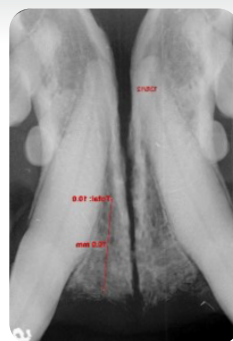PRE-OP



IMMEDIATE POST-OP  
PERIOMIX



5.5 MONTH FOLLOW UP



1 YEAR FOLLOW UP  
PRIOR TO IMPLANT  
PLACEMENT

#### PERIOMIX FOLLOWED BY FUSION

##### DX & PROCEDURE:

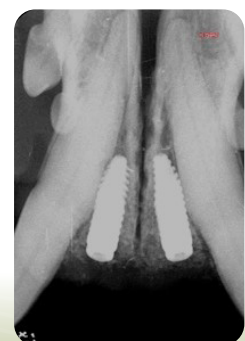Periodontal disease with grade 3 mobility of mandibular incisors. PERIOMIX placed at time of extraction to maintain bone height.

After 1 year, owner opted for implant placement. Implants surrounded by VTS FUSION.

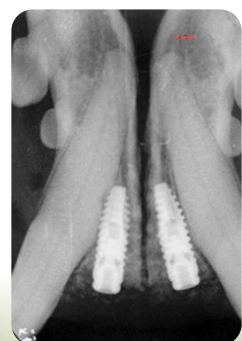
##### OBSERVATION:

Bone generated by PERIOMIX was excellent at 5 mo follow up; and maintained at implant placement (1 yr follow up).

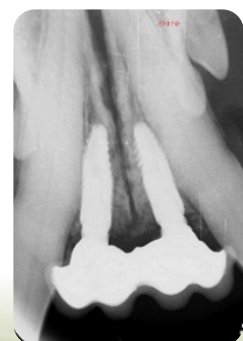
At 3 and 5 mos post implant placement with VTS FUSION, the mandibular bone was maintained with the implants very stable. Bone overgrowth was also noted at the 3.5 month impressions.



IMMEDIATE POST-OP  
FUSION



3.5 MONTH FOLLOW UP



5.5 MONTH FOLLOW UP