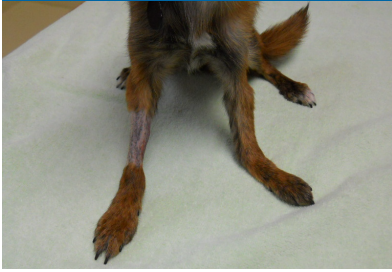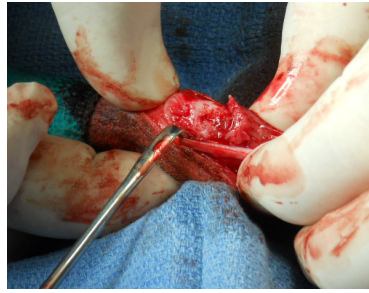


VTS Osteoallograft Orthomix Case 1 Fracture Repair

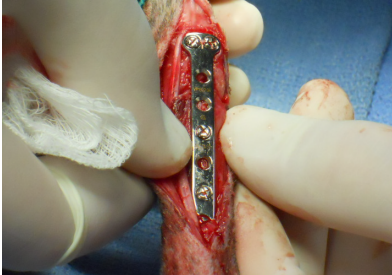

An osteopenic mixed breed dog presented with a radius ulna fracture that occurred subsequent to two previous fractures in the same leg. Both previous repairs were done without bone graft. →

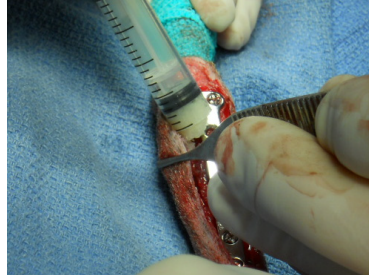


The fracture is exposed, debrided and prepared for plate placement.

Xena
5.6 pounds
Chihuahua mix

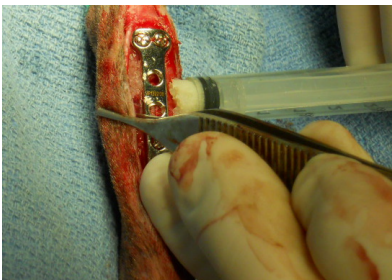


A 1.5 mm Synthes T plate is used to stabilize the fracture. →

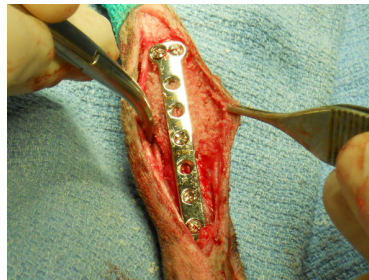

Osteoallograft® Orthomix® Ultra Fine is placed on the lateral and medial sides of the fracture.


The graft may also be mixed with patient blood prior to application.



Allograft particles increase surface area and provide increased amounts of native growth factors that attract osteoprogenitor cells to facilitate healing. →

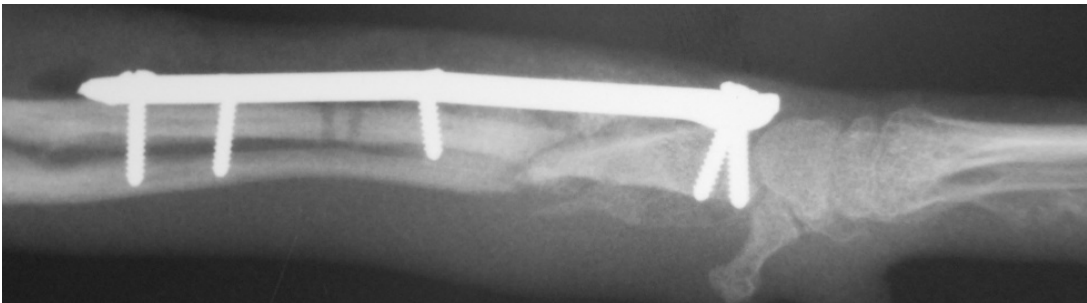


After placement of the bone allograft, the surgery site is ready for closure.



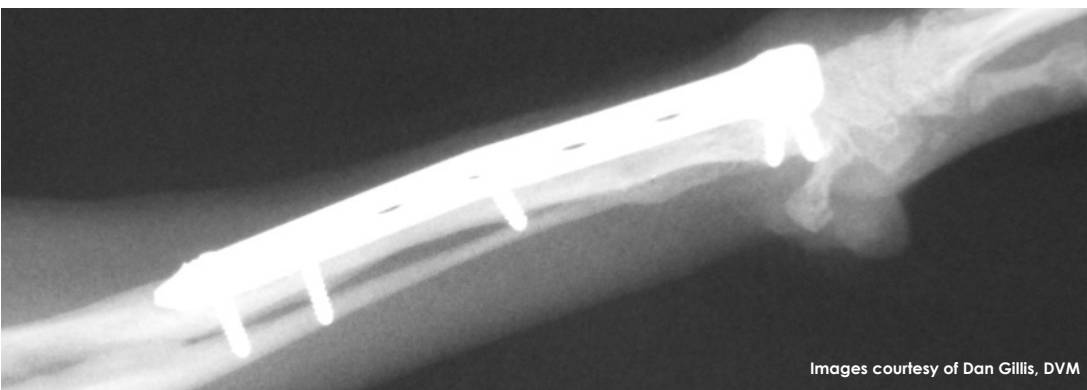
PRE OP:

The pre-op radiograph shows the re-fractured radius and ulna.



POST OP:

The post op radiograph shows the implant and the **Osteoallograft® Orthomix® Ultra Fine** placed around the fracture.



10 WEEK FOLLOW UP:

The fracture is fully healed.

Xena is weight-bearing and happy. Says Dr. Gillis, "I would highly recommend VTS bone grafts. They are easy to use and helped me tremendously with this case."

Images courtesy of Dan Gillis, DVM