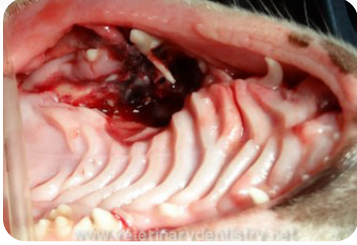
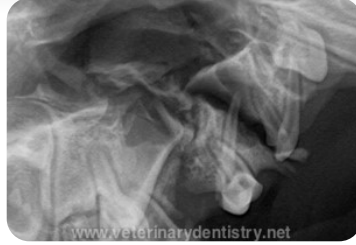
Ossiflex

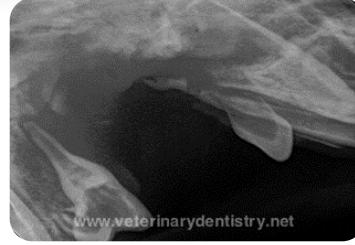ARNOLD 14 Week Puppy



PRESENTING TRAUMA

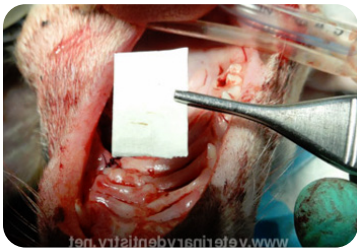


PRE-OP

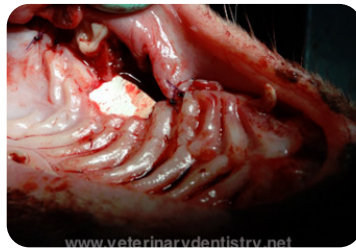

INTRA-OP FRAGMENTS REMOVED

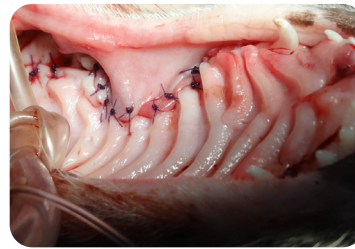DX:
Severe penetrating trauma and caudal fracture to right palate from dog bite.



OSSFIFLEX MEMBRANE



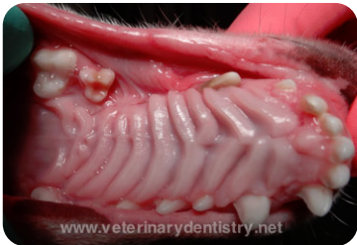ROSTRAL & CAUDAL CLOSURES



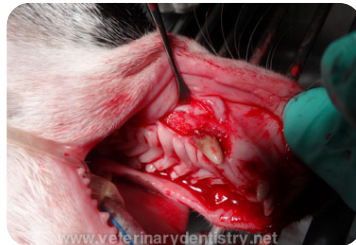TENSION-FREE

PROCEDURE:
Repair of penetration with Ossiflex membrane.

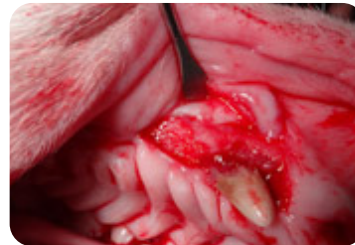
8 WEEK FOLLOW UP



8 WEEKS FOLLOW UP

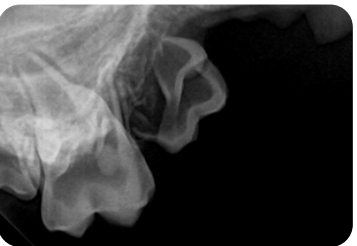

INTRA-OP TO REMOVE
DECIDUOUS ROOT TIP

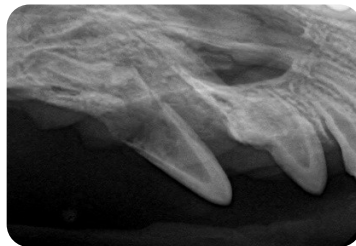

CLOSE UP SHOWS
NEW BONE FORMATION

OBSERVATION:
Good bone growth and closure of penetration by 8 weeks.



DECIDUOUS PREMOLAR &
CANINE ROOT TIP STILL PRESENT



FINAL APPEARANCE OF BONE GROWTH
AFTER EXTRACTION AT 8 WEEKS

