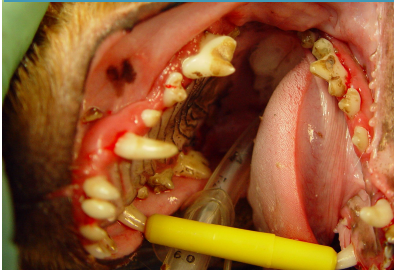
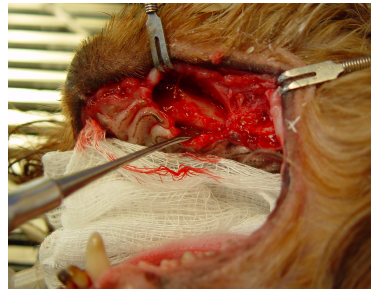


Case 1 Ossiflex Bone Membrane Case 1

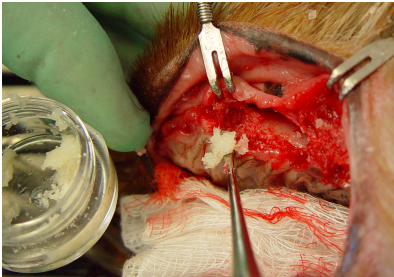
Guided Bone Regeneration (GBR)




A 2.5 year old Yorkshire Terrier presented with buccal bone loss in the maxilla necessitating extraction of all molars and premolars as well as the canine.



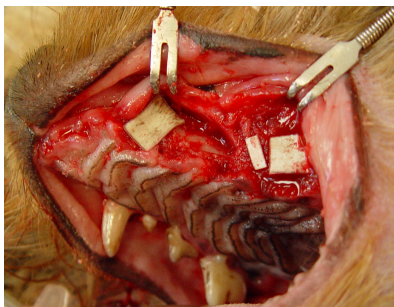
Extractions leave deep extraction sites prone to harbor bacteria leading to further bone loss and pain if left empty and untreated.



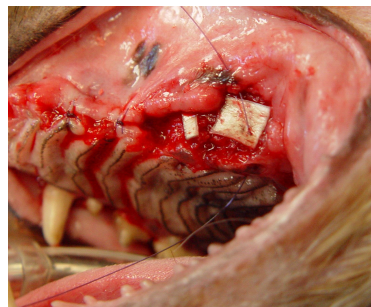
Osteoallograft® Periomix® is filled into the extraction sites for bone regeneration.



To prevent surrounding soft tissue from prematurely growing into the bone healing site, **Ossiflex® Bone Membranes** are placed over the bone graft. Shown here is the easy rehydration process.



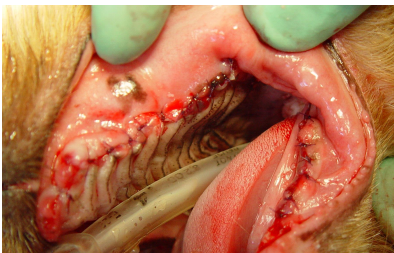
The **Ossiflex® Bone Membranes** are placed over the Periomix bone graft to prevent epithelial migration that may inhibit production of natural bone. This process is known as **Guided Tissue Regeneration**.



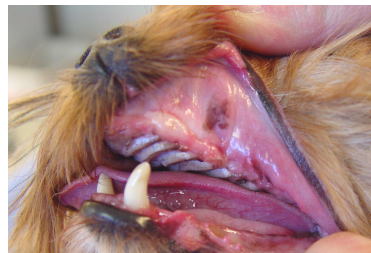
Bone membranes are sutured in place and soft tissue is sutured closed.



Alexis
2.5 years old
Yorkshire terrier

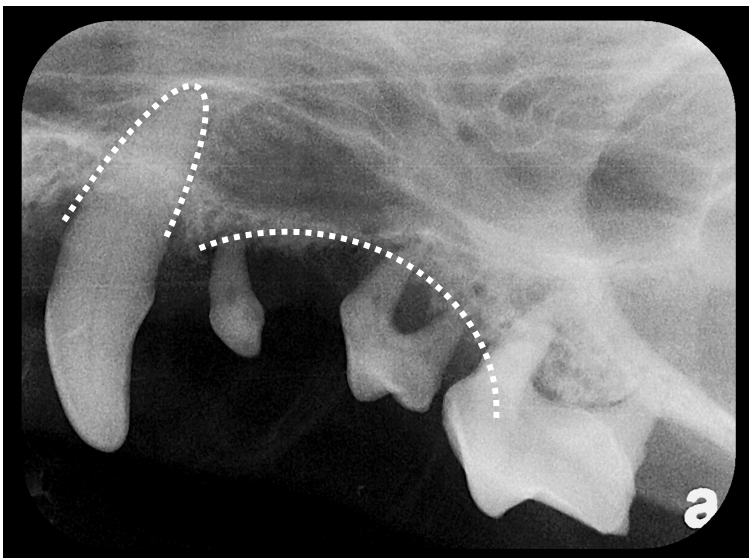


Sutures are in place and the surgery is complete.



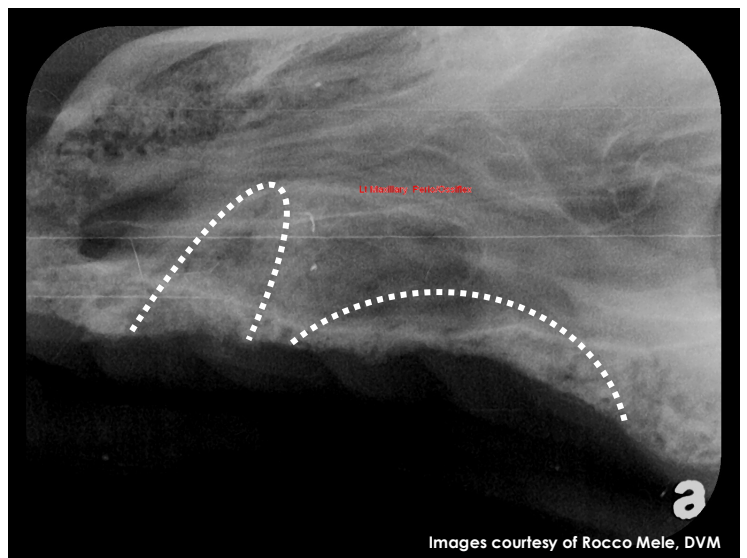
8 WEEK POST OP:

The extraction sites look nicely healed.



PRE OP:

The buccal bone loss is evident.



8 WEEK FOLLOW UP:

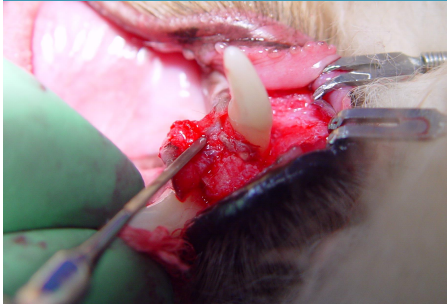
Radiographic evidence demonstrates that extraction sites are filled with solid bone. Significant gain in alveolar ridge height was achieved.

Images courtesy of Rocco Mele, DVM

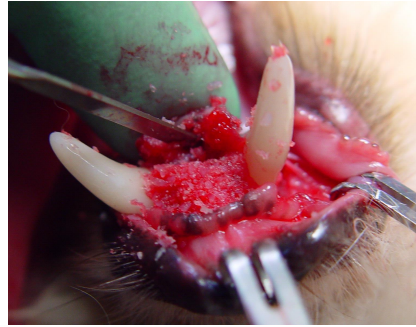
See over for Case 2 >>>

VTS Ossiflex Bone Membrane Case 2

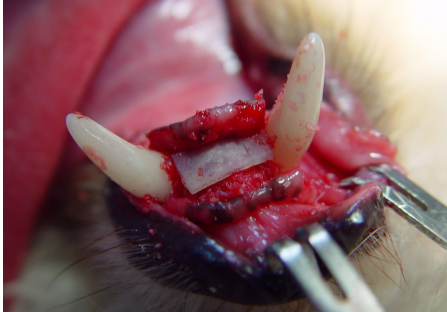Guided Tissue Regeneration (GTR)



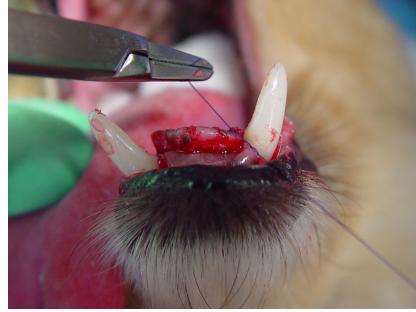An 8 year-old Doxie mix presented with marginal mandibular weakness (symphyseal mobility). All incisors and fibrous cartilage were removed.



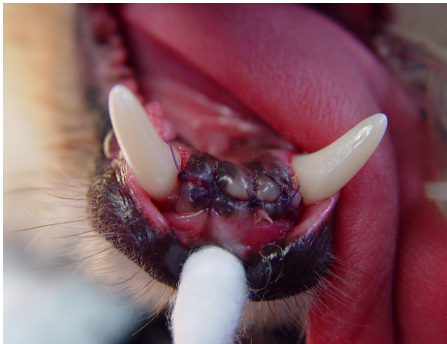A surgical flap is created and **Osteoallograft® Periomix®** is filled into the newly created bone voids.



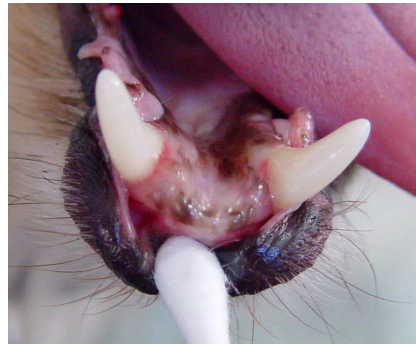An **Ossiflex® Bone Membrane** is placed on top of the particulate bone graft to prevent premature soft tissue in-growth. This technique is called **Guided Tissue Regeneration**.



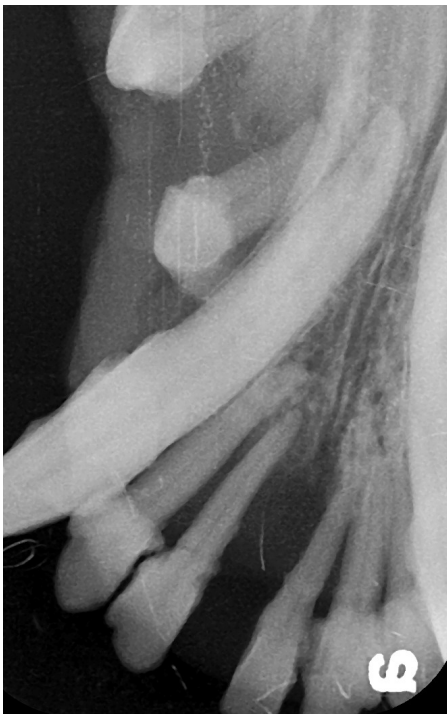The surgical flap is sutured closed.



Sutures are in place and the surgery is complete.

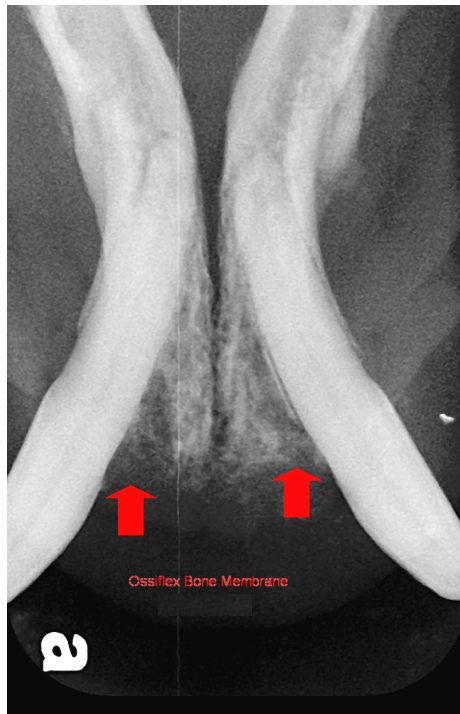

8 WEEK POST OP:
At 8 weeks post op, the surgery site is healed with obvious stability.



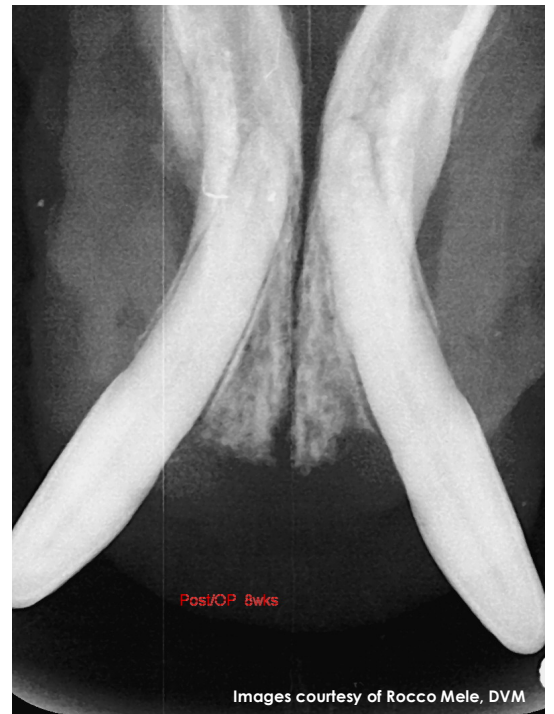PRE OP:

Significant horizontal bone loss between the canines necessitating extraction of the incisors.



POST OP:

Bone voids are filled with **Osteoallograft® Periomix®** which is covered by an **Ossiflex® Bone Membrane**.



8 WEEK FOLLOW UP:

Bone voids are filled with solid and completely integrated new bone providing a solid foundation for the canine teeth.