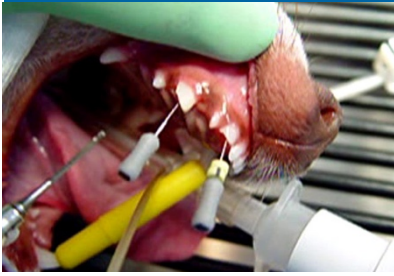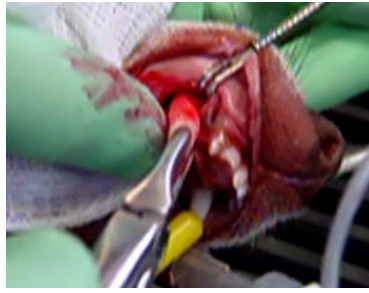


vis Osteoallograft Periomix Case 7 Dental Implant

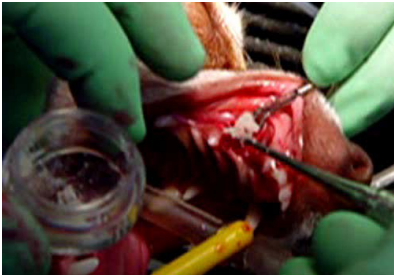

2.5 year-old Chihuahua mix presented with face trauma creating a canine and incisor fracture with pulp exposure. Also note a deformed lateral incisor.

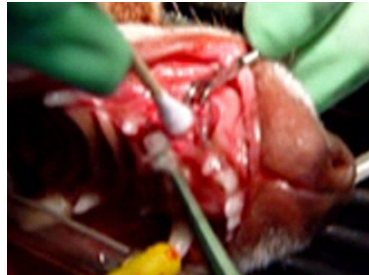

All involved teeth were atraumatically extracted to preserve as much alveolar bone as possible.

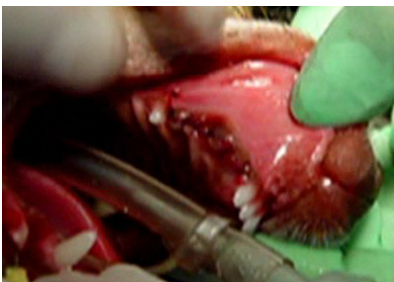Sam
2.5 years old
Chihuahua mix



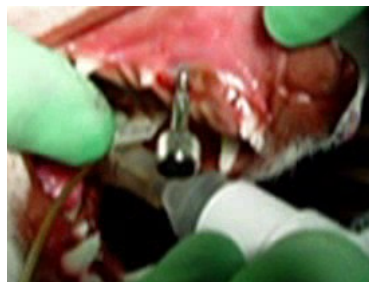
The extraction site is filled with **Osteoallograft® Periomix®**.



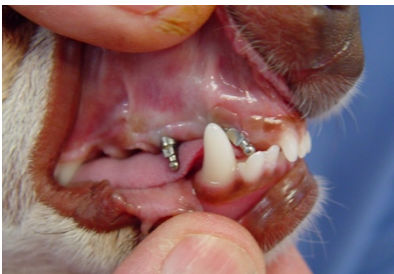The bone allograft is compacted into the apical area of the alveolus to ensure complete and dense filling.



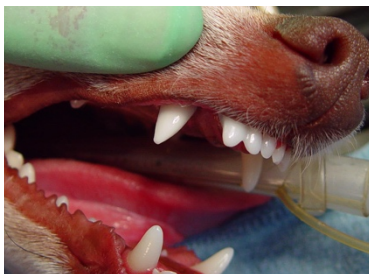After all affected teeth were surgically extracted and grafted, the gingival flap has been sutured closed.



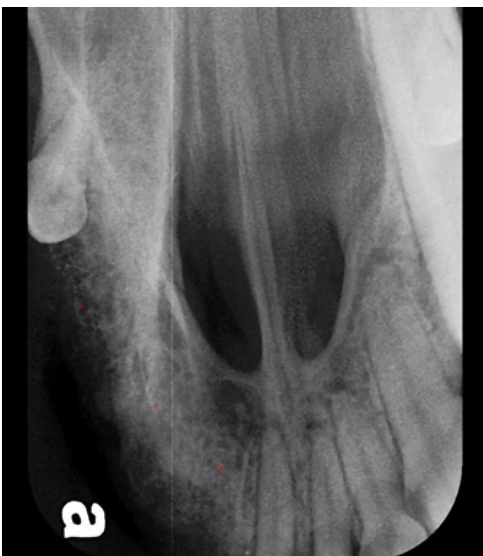12 weeks after placement of the **Osteoallograft® Periomix®** bone allograft, radiographs show dense bone ready for two mini implants to be seated.



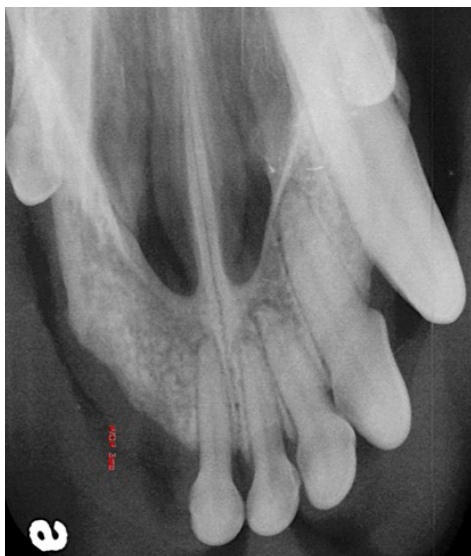24 weeks after the extractions, the implants are immobile and ready for the impressions.



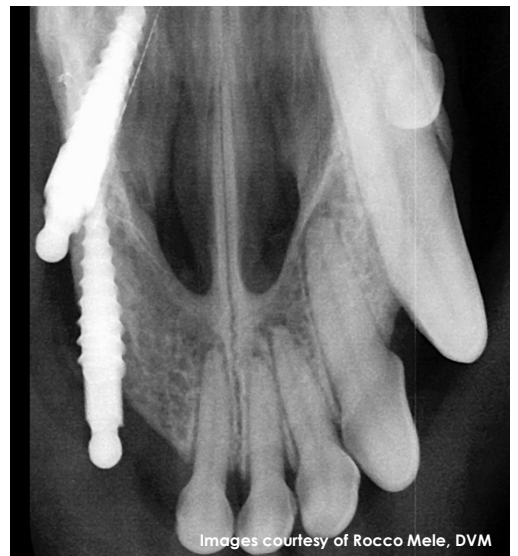The canine pontic and a 2-unit bridge are cemented onto the abutments. They are beautiful and – most importantly – rock solid.



POST OP:
Extraction sites are filled with **Osteoallograft® Periomix®**.



12 WEEK FOLLOW UP:
At 12 weeks, the radiograph shows dense bone. Says Dr. Mele, “We are into very, very good bone [suitable for implants].”

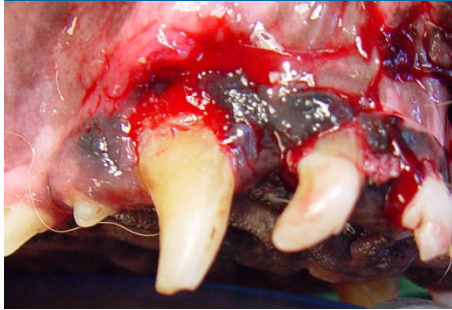


24 WEEK FOLLOW UP:
At the 24 week follow-up, the implants are anchored into the maxilla and ready for bridge placement.

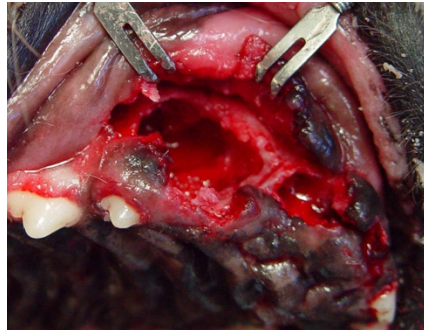
Images courtesy of Rocco Mele, DVM

VTS Cancellous Bone Block Case

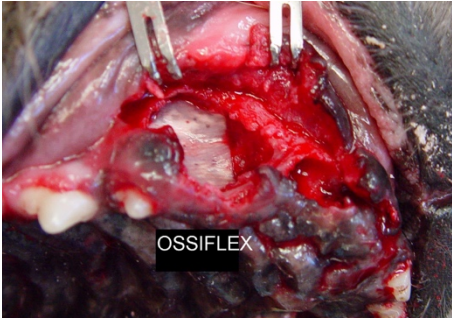
Large Extraction Site



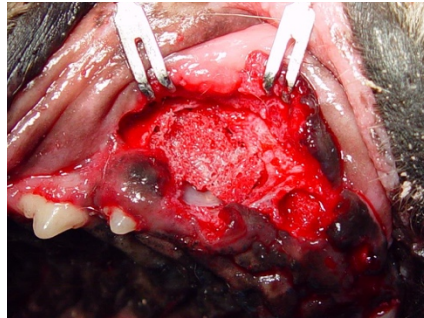
11 year-old Australian Shepherd named Rosie presented with a fractured canine, gingival edema and deep palatal infrabony pockets.



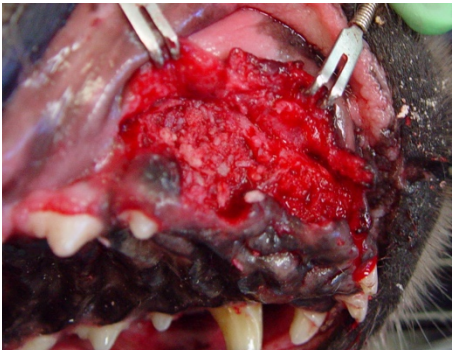Only after affected teeth were extracted and the inflammatory tissue was removed from the socket, could the extensive damage to the alveolar bone be seen.



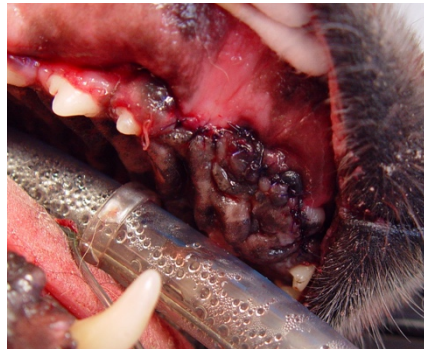The alveolar-nasal defect was repaired with a flexible laminar bone graft (**Ossiflex™ Bone Membrane**).



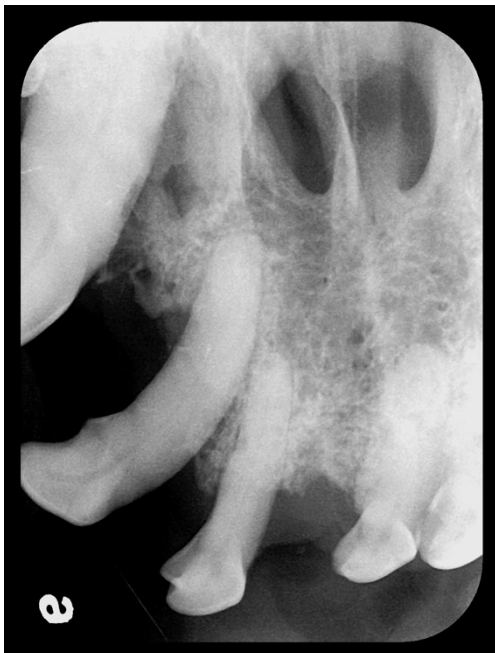The large extraction site is then filled with a cancellous bone block allograft from VTS.



Osteoallograft® Periomix® is placed around the coronal and apical area of the cancellous block for a complete fill of the extraction site.

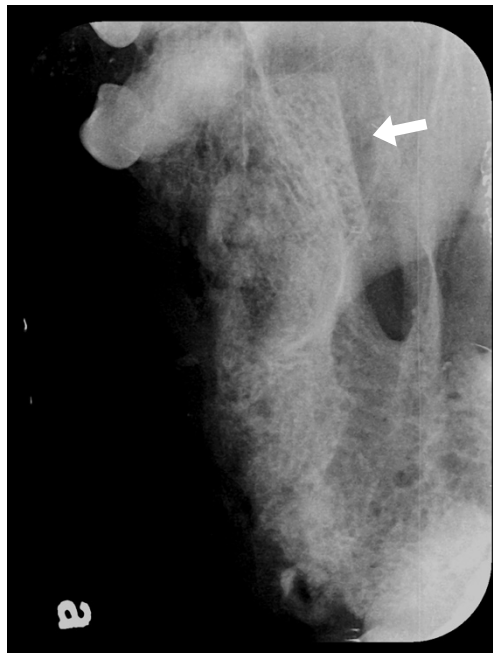


The gingival flap is sutured closed.



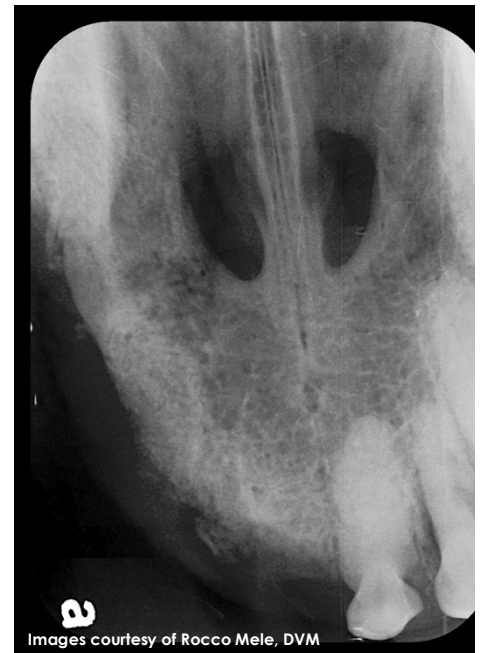PRE OP:

The pre-op radiograph shows bone loss resulting from necrosis of the supporting bone. Note the nasal fistula tract.



POST OP:

The post-op radiograph shows the margins of the cancellous bone block allograft in the extraction site surrounded by **Osteoallograft® Periomix®**.



Images courtesy of Rocco Mele, DVM

4 WEEK FOLLOW UP:

At only 4 weeks post surgery, the cancellous block appears fully integrated into the host bone and bone density has significantly improved.