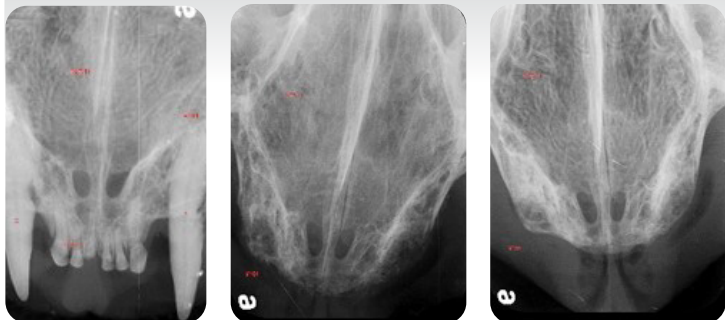


Periomix®

LUCY 11 Year Old Domestic Shorthair



PRE-OP

IMMEDIATE
POST-OP

2 MONTH
FOLLOW UP

PERIOMIX + MEMBRANE

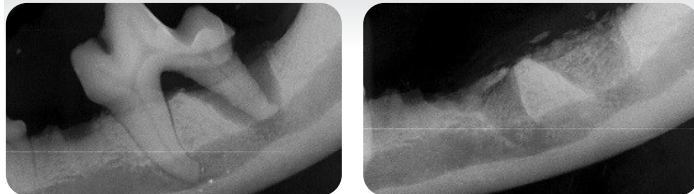
DX & PROCEDURE:

Odontoclastic resorptive lesions affecting incisors and canines. Extraction site defect filled with VTS Periomix.

OBSERVATION:

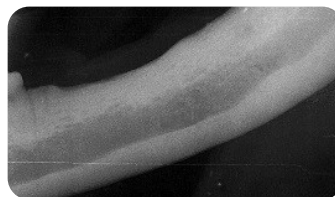
Excellent bone remodeling at 2 mos.

SHADOW 11 Year Old Poodle



PRE-OP

IMMEDIATE POST-OP



7 MONTH FOLLOW UP

PERIOMIX + MINI BLOCK + MEMBRANE

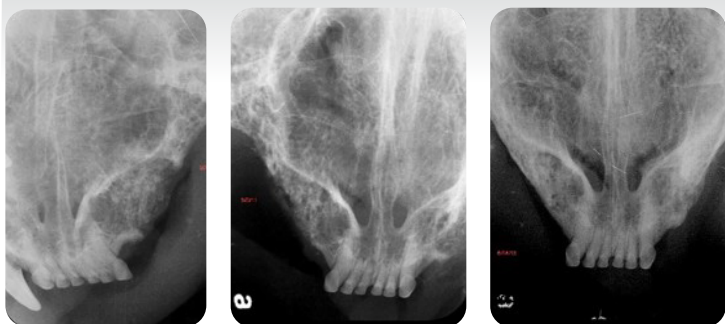
DX & PROCEDURE:

Vertical and horizontal bone loss due to periodontitis. Extraction site filled with VTS Mini-Block and Periomix.

OBSERVATION:

Dense superior cortex and normal anatomy without further bone loss.

NAKITA 15 Year Old Japanese Bobtail



INTRA-OP

IMMEDIATE
POST-OP

2.5 YEAR
FOLLOW UP

PERIOMIX + OSSIFLEX

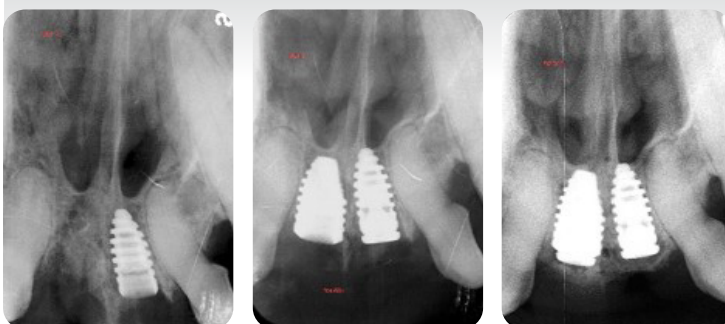
DX & PROCEDURE:

Alveolar osteitis and surgical extraction of maxillary canines. Repaired with VTS Periomix and Ossiflex Membrane.

OBSERVATION:

Excellent bone remodeling maintained at 2.5 yrs, note strong buccal margins.

BAILEY 7 Year Old Schnauzer



INTRA-OP

IMMEDIATE
POST-OP

1 YEAR
FOLLOW UP

PERIOMIX + MEMBRANE

DX & PROCEDURE:

Periodontal disease with deep pockets. Four incisors surgically extracted with immediate implant placement and augmentation to maintain incisal bone. Owner plans for future restorations. Repaired with VTS Periomix & membrane.

OBSERVATION:

Excellent maintenance of incisal area with new bone growth covering access screws. No bone loss or tissue regression at 1 yr.