

# SYNERGY™

## Humeral Fracture Revision

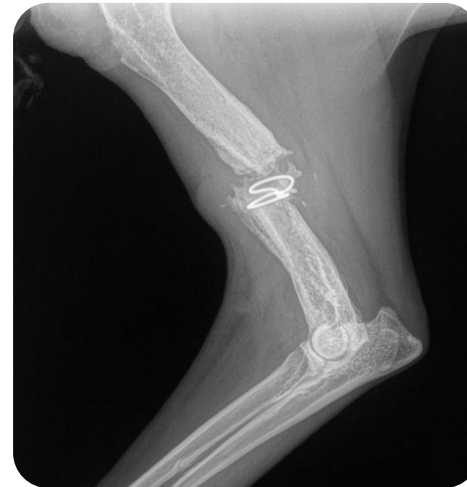Robin Hood was found by a rescue with a fractured left humerus. After the pin migrated out twice, Robin Hood was referred to Dr. Zeltzman for revision. The bone was repaired using a plate and **Synergy** synthetic bone graft to speed up the healing process.

After only a month of confinement at the rescue, x-rays showed the bone healed nicely. To ensure Robin Hood's bone had fully healed enabling him to hunt and feed for himself again, he was kept for another month. After two months, additional x-rays were taken and confirmed the bone had completely healed so Robin Hood was released into the wild.

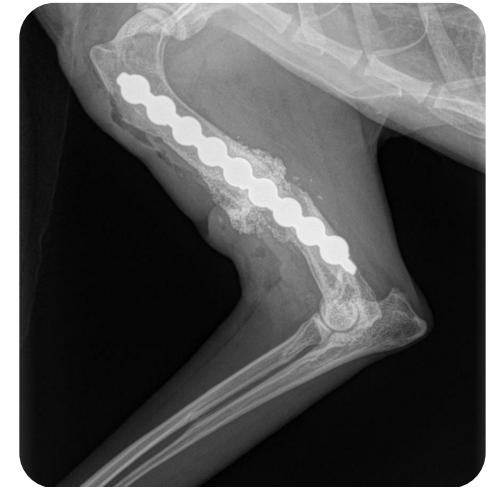


Robin hood heading home to the wilderness.

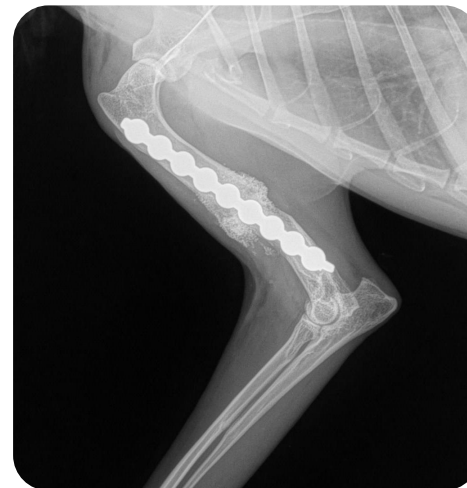
**ROBIN HOOD**  
 2 year-old  
 Red Fox  
 Humeral Fracture Revision



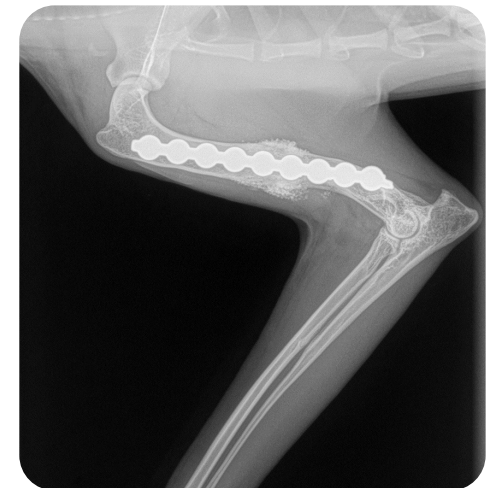PRE-OP



INTRA-OP



1 MONTH POST-OP



2 MONTHS POST-OP