

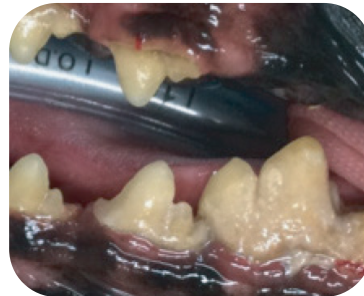SYNERGY™

Advanced Bioactive Bone Graft Material

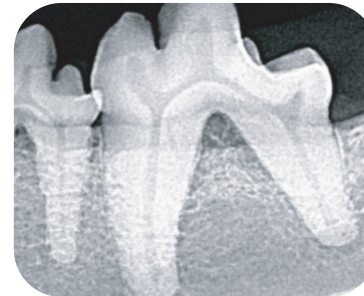
Wombat Stewart, a Dachshund, presented with furcation (F2) exposure and increased periodontal probing depths buccally at 309.

The furcation defect was filled with SYNERGY Bioactive Bone Graft

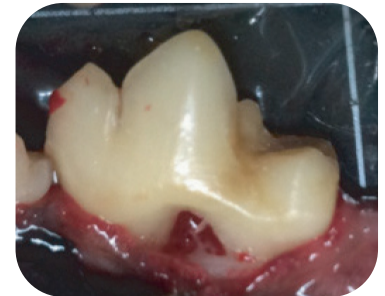At the 6 & 14 month follow-ups, the tooth appeared healthy with a normal 2 mm sulcus depth in spite of minimal home care. Radiographs indicate new bone formation in furcation.



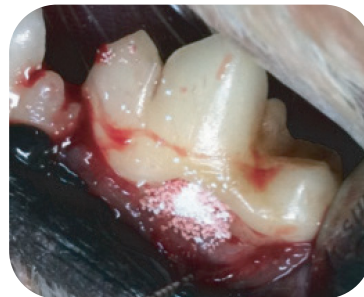Furcation exposure and probing depth 7-9 mm



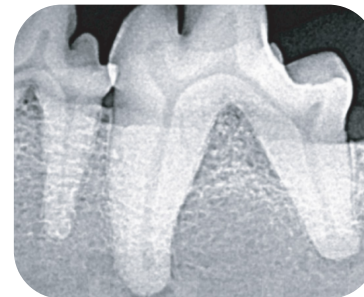
Horizontal bone loss



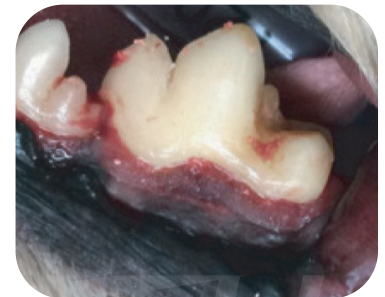Furcation defect after cleaning and root planning



Placement of SYNERGY

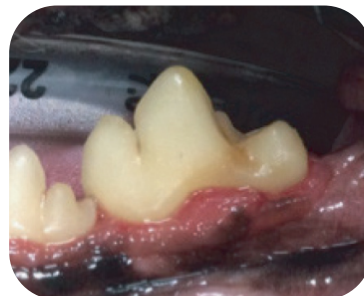

Radiographic appearance

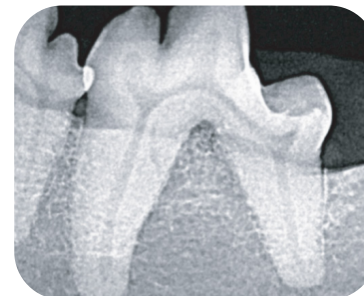

Envelope flap is superglued closed

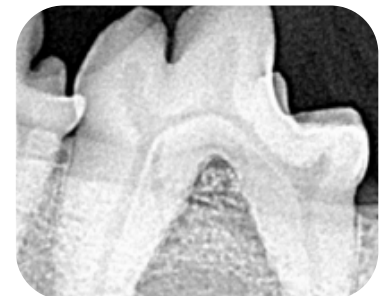6 Months Later



Normal gingival height and probing depth 1-2 mm



Furcation bone height restored



Normal 2mm probing depth

14 Months Later



CASE STUDY: WOMBAT STEWART

Dachshund
Periodontal disease

