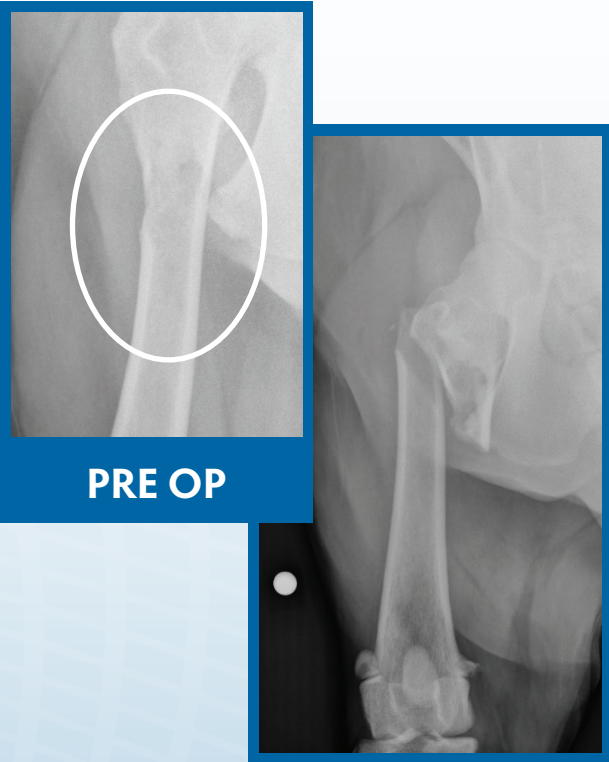
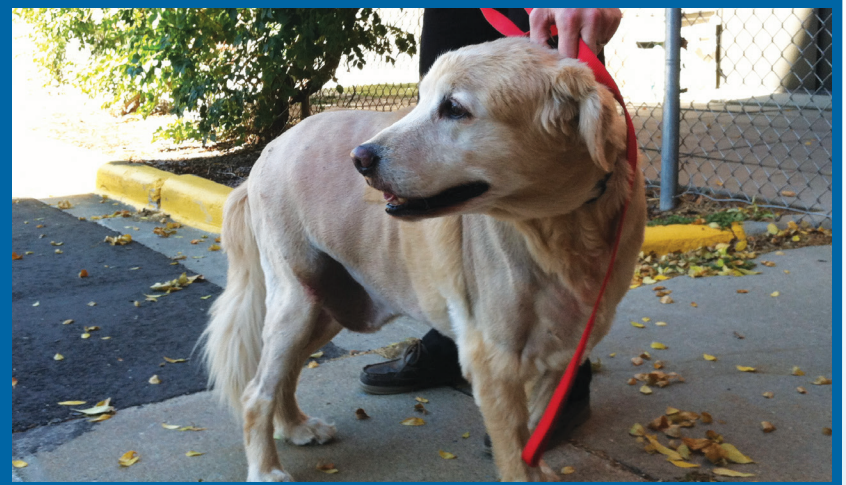
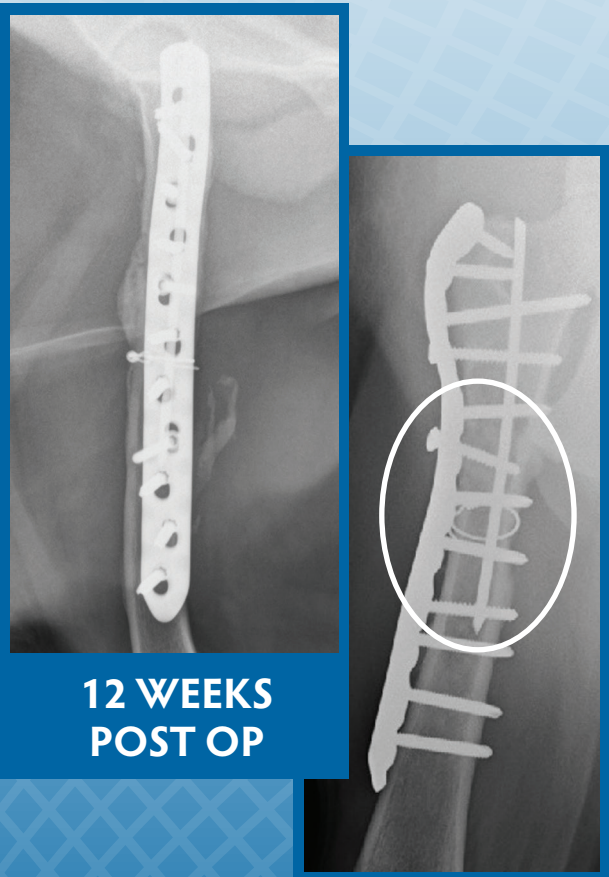


PRE OP

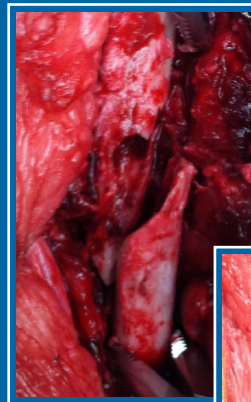


Barley is a 10 year old Golden Retriever who presented for lameness and fractured his femur in hospital during the workup / staging. The primary tumor (Sarcoma) was curetted, then plated and stabilized with internal fixation across the fracture gap. VTS Orthomix® and cancellous autograft were used to fill the defect. The site went on to union at 12 weeks.

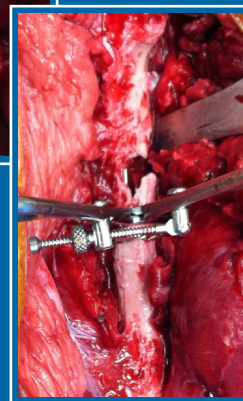
Barley is still doing well now 6 months post op. His current treatment is monthly Pamidronate. (April, 2013)



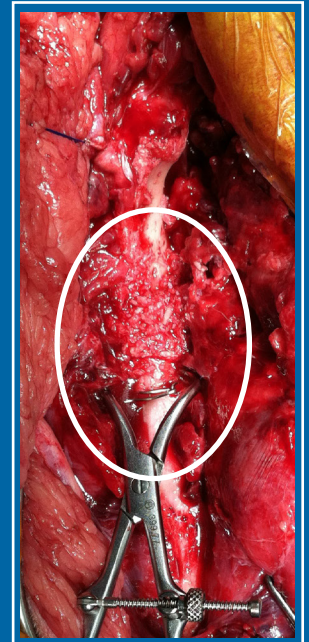
12 WEEKS POST OP



FRACTURE



REDUCTION



PACKED WITH BONE GRAFT

Case and photos courtesy of Dr. Jason Bleedorn, University of Wisconsin, School of Veterinary Medicine