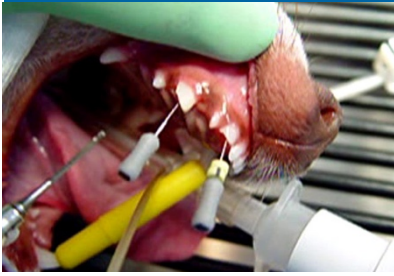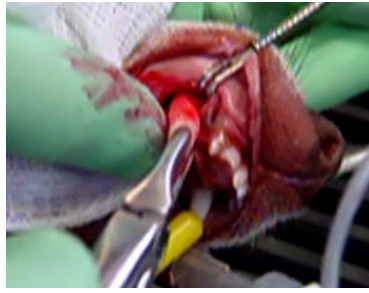


vis Osteoallograft Periomix Case 7 Dental Implant

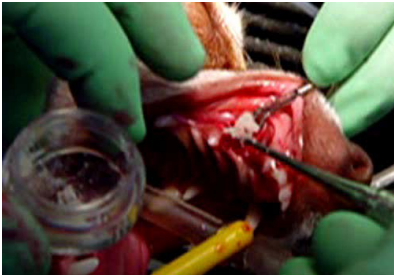

2.5 year-old Chihuahua mix presented with face trauma creating a canine and incisor fracture with pulp exposure. Also note a deformed lateral incisor.

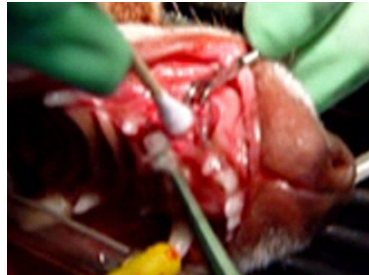

All involved teeth were atraumatically extracted to preserve as much alveolar bone as possible.

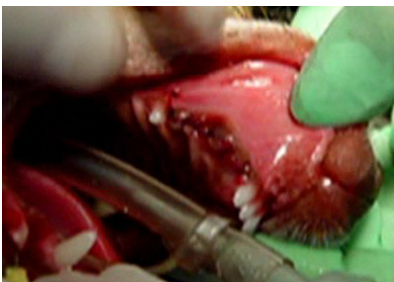Sam
2.5 years old
Chihuahua mix



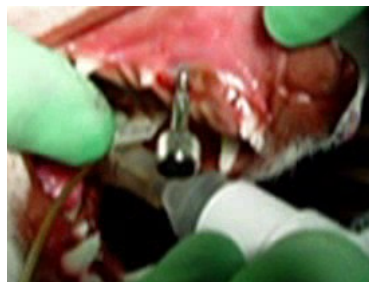
The extraction site is filled with **Osteoallograft® Periomix®**.



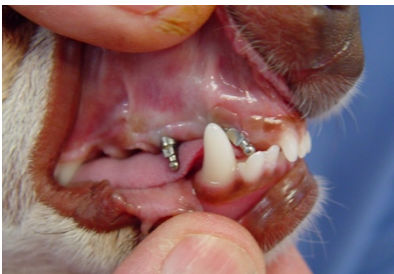The bone allograft is compacted into the apical area of the alveolus to ensure complete and dense filling.



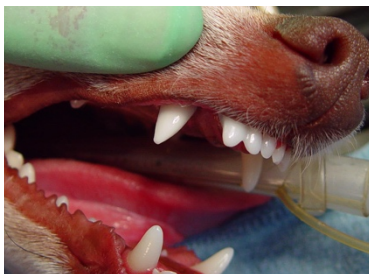After all affected teeth were surgically extracted and grafted, the gingival flap has been sutured closed.



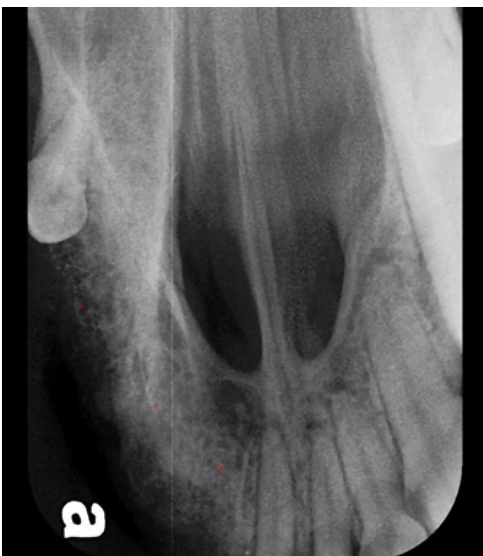12 weeks after placement of the **Osteoallograft® Periomix®** bone allograft, radiographs show dense bone ready for two mini implants to be seated.



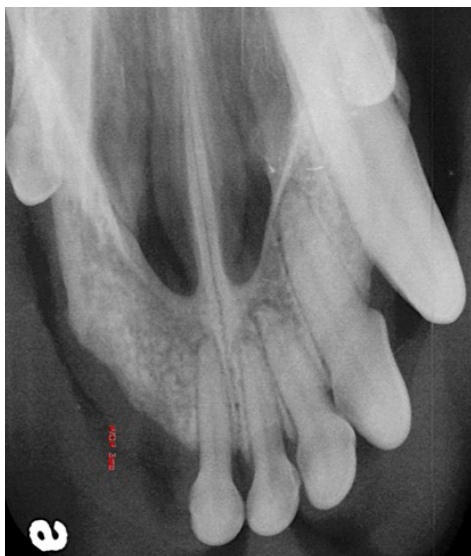24 weeks after the extractions, the implants are immobile and ready for the impressions.



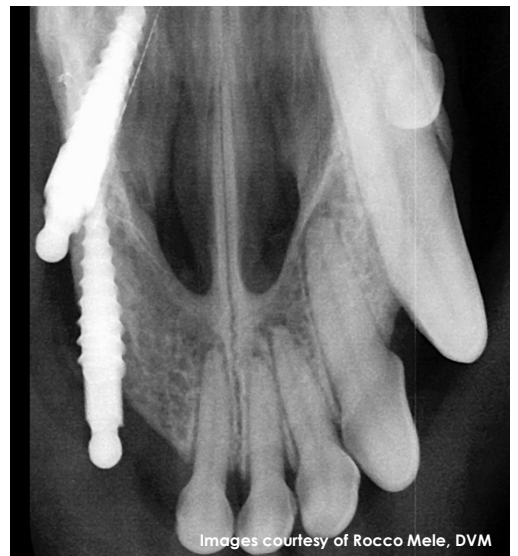The canine pontic and a 2-unit bridge are cemented onto the abutments. They are beautiful and – most importantly – rock solid.



POST OP:
Extraction sites are filled with **Osteoallograft® Periomix®**.



12 WEEK FOLLOW UP:
At 12 weeks, the radiograph shows dense bone. Says Dr. Mele, “We are into very, very good bone [suitable for implants].”



24 WEEK FOLLOW UP:
At the 24 week follow-up, the implants are anchored into the maxilla and ready for bridge placement.

Images courtesy of Rocco Mele, DVM