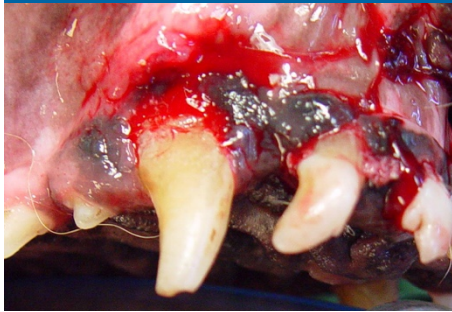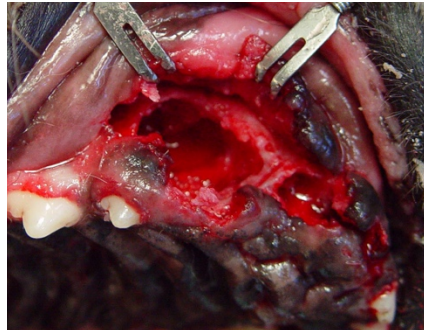


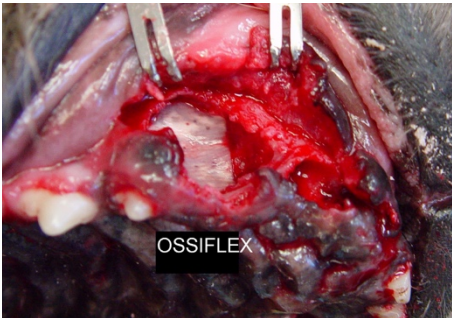
VTS Cancellous Bone Block Case **Large Extraction Site**



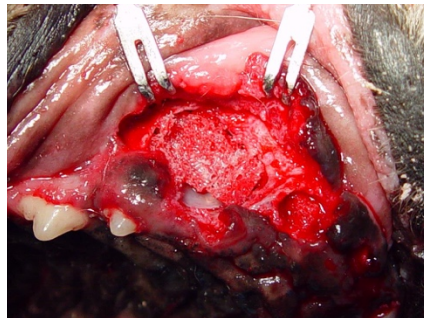
11 year-old Australian Shepherd named Rosie presented with a fractured canine, gingival edema and deep palatal infrabony pockets.



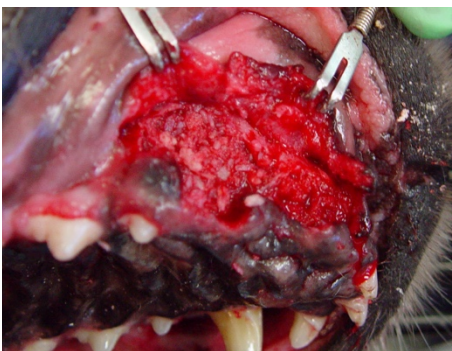Only after affected teeth were extracted and the inflammatory tissue was removed from the socket, could the extensive damage to the alveolar bone be seen.



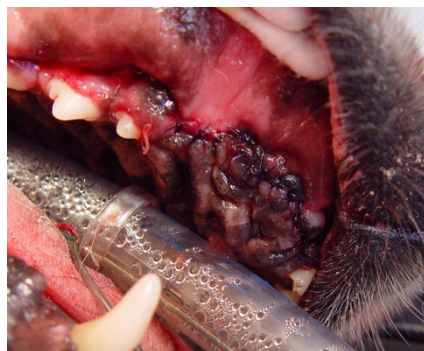The alveolar-nasal defect was repaired with a flexible laminar bone graft (**Ossiflex™ Bone Membrane**).



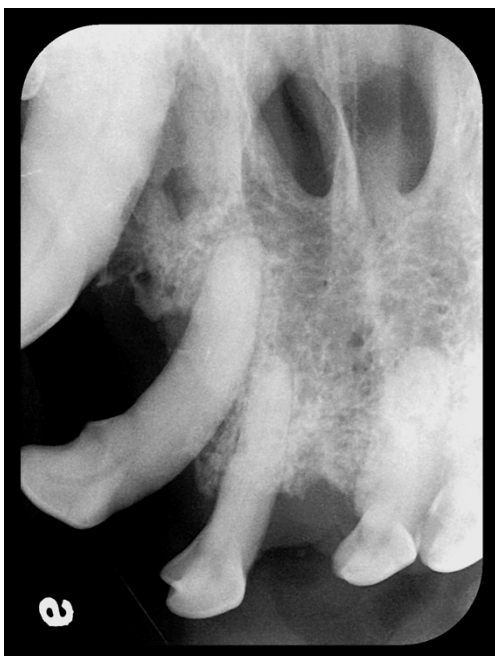The large extraction site is then filled with a cancellous bone block allograft from VTS.



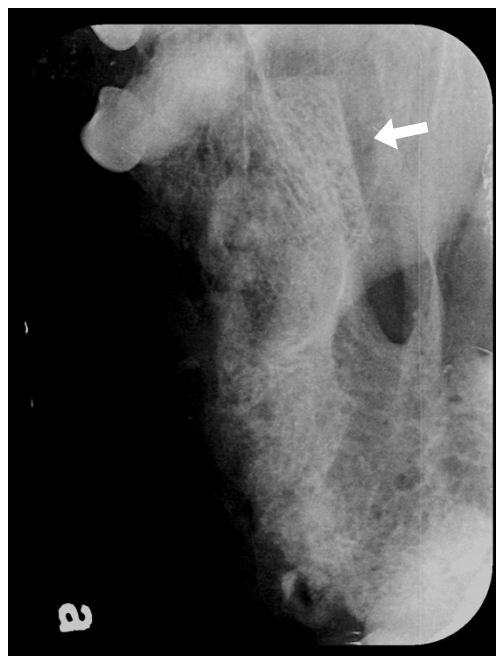
Osteoallograft® Periomix® is placed around the coronal and apical area of the cancellous block for a complete fill of the extraction site.



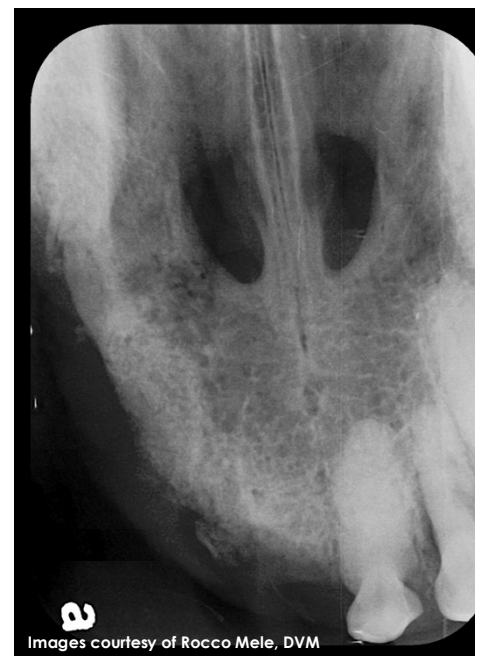The gingival flap is sutured closed.



PRE OP:
The pre-op radiograph shows bone loss resulting from necrosis of the supporting bone. Note the nasal fistula tract.



POST OP:
The post-op radiograph shows the margins of the cancellous bone block allograft in the extraction site surrounded by **Osteoallograft® Periomix®**.



4 WEEK FOLLOW UP:
At only 4 weeks post surgery, the cancellous block appears fully integrated into the host bone and bone density has significantly improved.