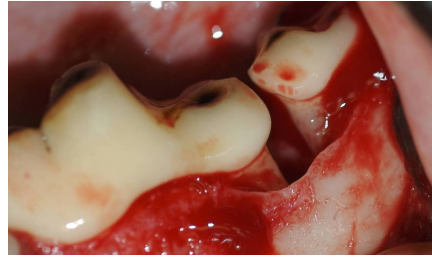
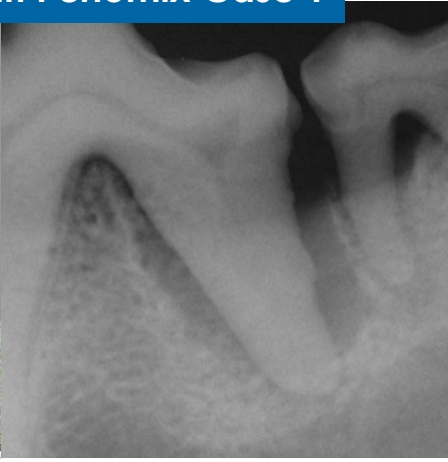


## vs Osteoallograft Periomix Case 1 Preserving Teeth

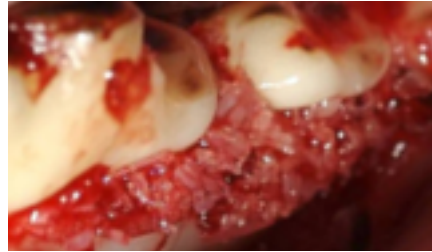
### PRE OP:

Horizontal bone loss reduced the height of the alveolar margin; there was a significant component of vertical bone loss around the distal root.

Reggie  
12 y/o retired  
Border Collie



A surgical flap was created. Periodontal disease had caused a marked degree of bone loss that would generally be treated by extraction.

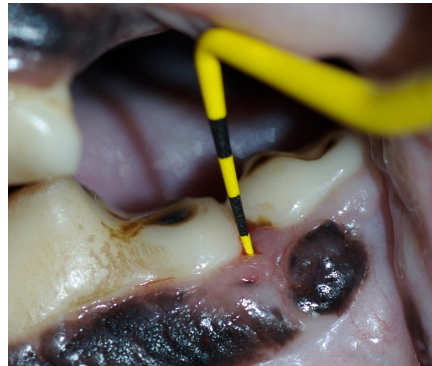
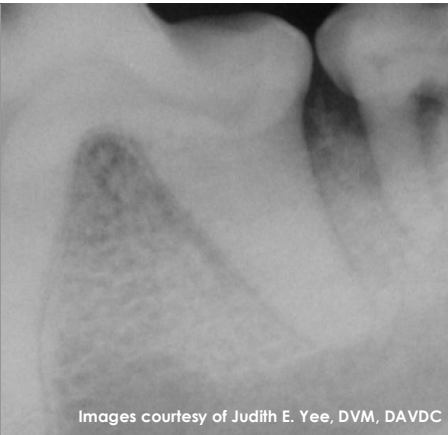
Mixed with patient blood, **Osteoallograft® Periomix®** was packed into surgical site. Doxirobe gel was then added as GTR barrier.

### 8 WEEK FOLLOW UP:

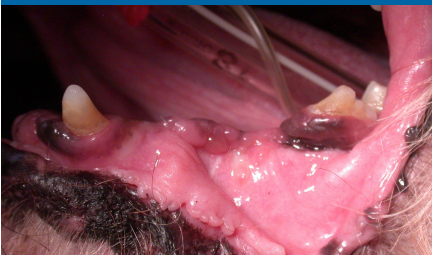
The gingival defect has completely healed with no recession at the site. "This outcome was quite remarkable," said Dr. Yee, "Ordinarily at least part of that tooth would have required extraction."

Images courtesy of Judith E. Yee, DVM, DAVDC

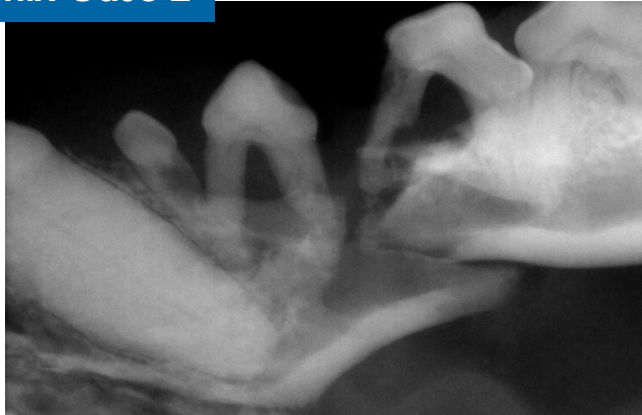


Follow-up at 8 weeks: Reconstruction of periodontium to a 2 mm probing depth has occurred and extraction has been avoided.

## vs Osteoallograft Periomix Case 2 Bilateral Mandibular Fracture Repair

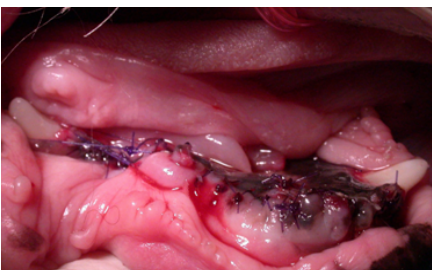


Bilateral mandibular fractures left the entire rostral right and left mandibles mobile.

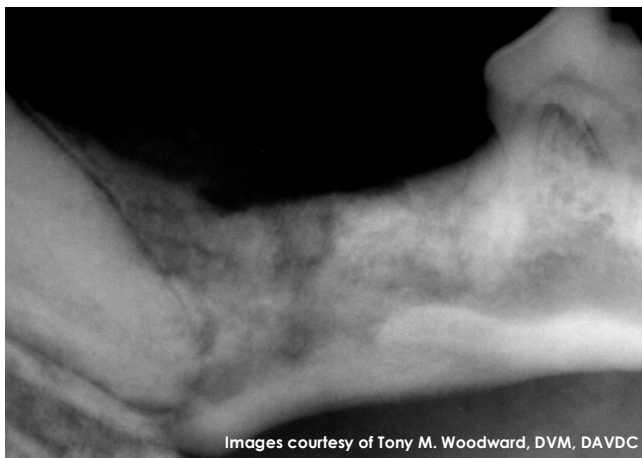

### PRE OP:

Although the fractures had occurred after the patient had been bitten by another dog, it was apparent from pre-op radiographs that severe periodontal disease played a significant role in these fractures.




Mobile teeth were extracted, **Osteoallograft® Periomix®** was placed, and soft tissues were closed. Supporting sutures helped raise the front of the mandible. No implants were used.



Images courtesy of Tony M. Woodward, DVM, DAVDC

### 12 WEEK FOLLOW UP:

Both fracture sites were well-healed and had filled in with normal bone. No mobility was present. Said Dr. Woodward, "To say I am amazed would be putting it lightly."



Mickey  
12 y/o  
Lhasa Apso


See over for Case 3 and Case 4 >>>

## VTs Osteoallograft Periomix Case 3

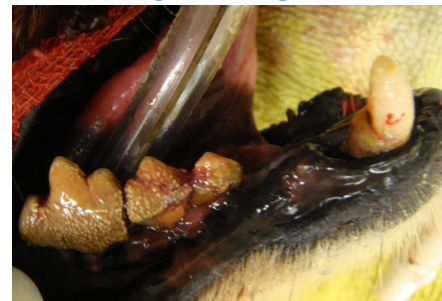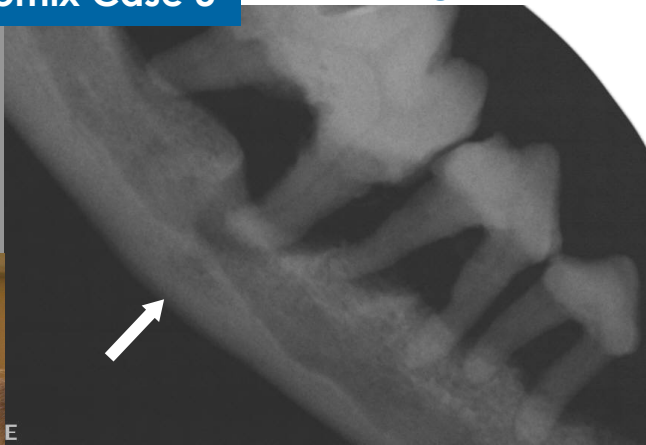## Preventing Fracture / Preserving Strength

### PRE OP:

Severe periodontal disease resulted in >50% horizontal and vertical bone loss. There was significant potential for a mandibular fracture.



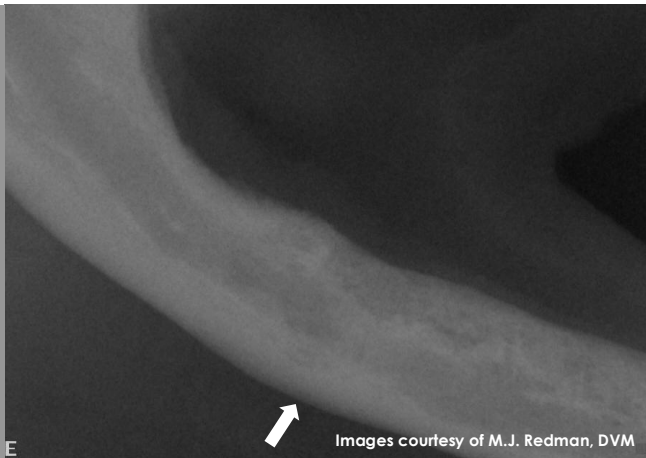
Sapper  
10 y/o  
Chihuahua mix



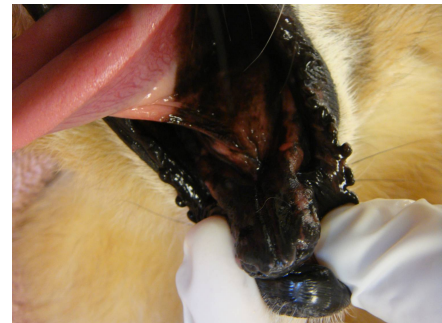
Right mandible before surgery. There was marked calculus and periodontal disease.

### 10 WEEK FOLLOW UP:

Extraction sites have filled in with new bone. Ventral and dorsal mandibular structures have increased density. Potential for a mandibular fracture has been decreased significantly. Without **Osteoallograft® Periomix®**, healing would have taken considerably longer and the patient would have been at risk of fracture for a much longer time.



Images courtesy of M.J. Redman, DVM



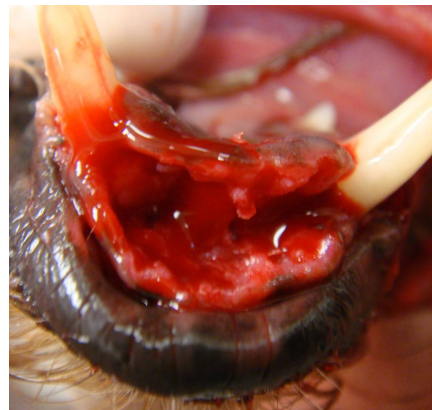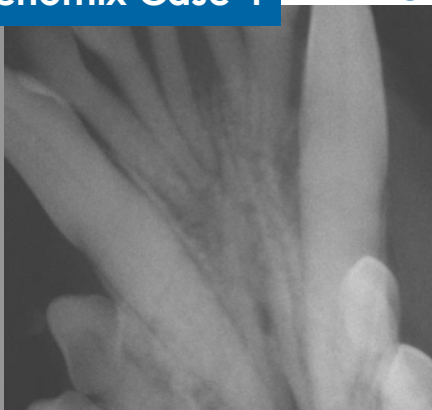At 10-weeks following grafting with **Osteoallograft® Periomix®**, the mandible was palpably stable.

## VTs Osteoallograft Periomix Case 4

## Saving Canines

### PRE OP:

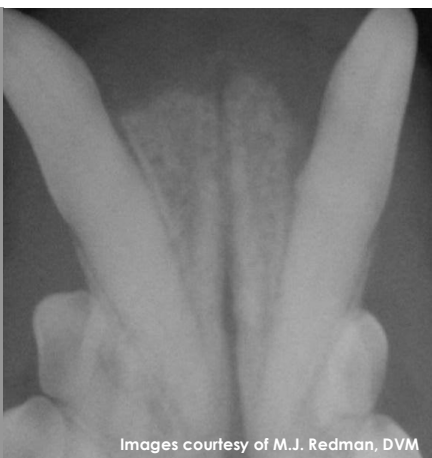
One mandibular incisor was missing and the rest were mobile. The canines had 6 mm mesial pockets and there was >50% bone loss. The extreme loss of bone increased the risk of loss of both canine teeth.



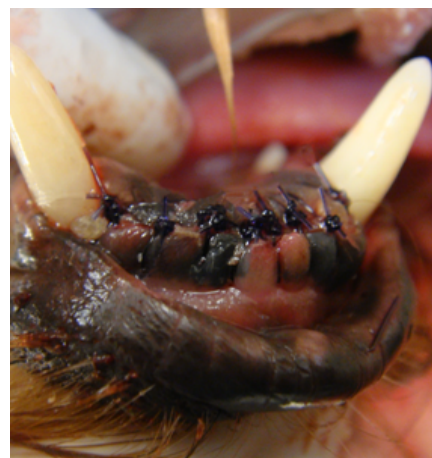All incisors had to be extracted, leaving deep extraction sites. Bone stock was compromised, raising concern that the canines would exfoliate.

### 8 WEEK FOLLOW UP:

Probing revealed no pockets. The risk of exfoliation of the canines had been significantly reduced. Without **Osteoallograft® Periomix®** the remaining bone and soft tissues would have healed with more of the roots exposed to the oral cavity, thus increasing the risk of continued periodontitis and subsequent exfoliation of the canines.



Images courtesy of M.J. Redman, DVM



**Osteoallograft® Periomix®** was used to fill the extraction sites, Doxirobe gel was added, and the soft tissues were sutured closed.



Dex  
3 y/o  
Yorkie