



Periomix®

vs.

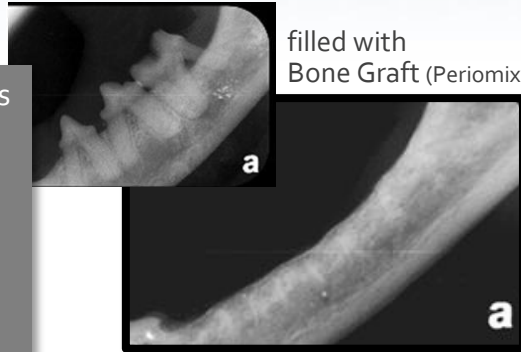Bioglass

Left:
filled with
Bone Graft (Periomix)

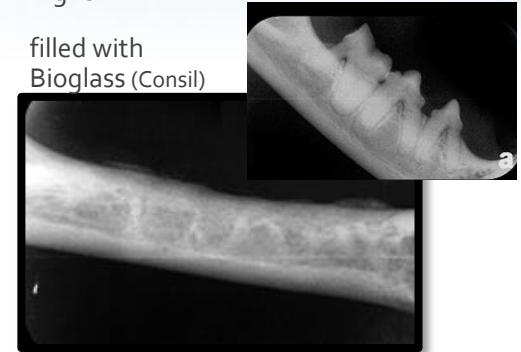
Same Patient:
7.5 yr feline
plasmacytic stomatitis

Right:
filled with
Bioglass (Consil)

Only real bone graft is capable of regenerating normal anatomy, fully integrating with the host bone and maintaining ridge height.



Normal anatomy emerging with good integration.



Scalloped margins still evident, granularity still visible.

6 wks follow up

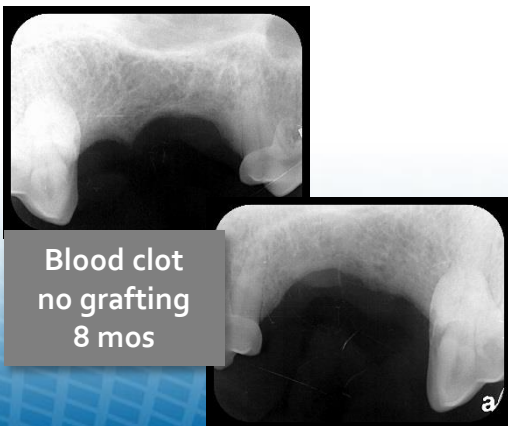Blood Clot

vs.

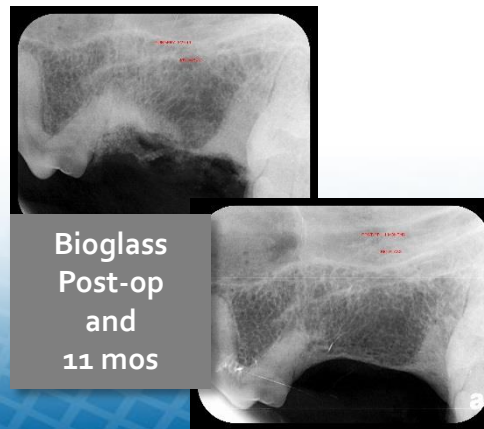
Bioglass

vs.

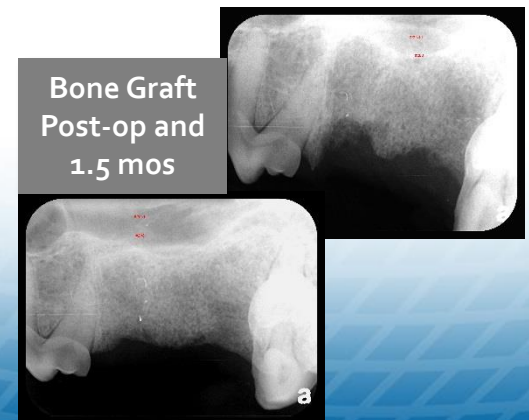Bone Graft



Blood clot
no grafting
8 mos



Bioglass
Post-op
and
11 mos



Bone Graft
Post-op and
1.5 mos



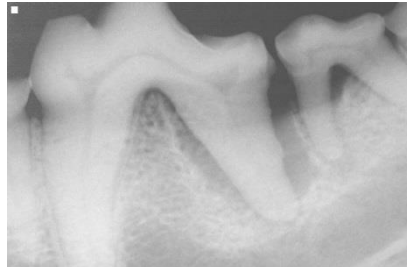Would you extract or preserve?

Treat periodontitis plus graft (Periomix)

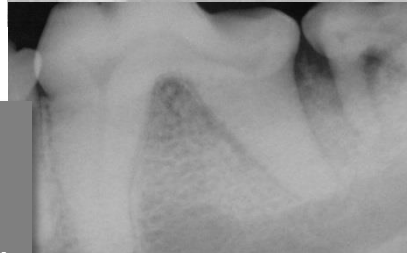12 yr Border Collie:

Severe vertical and horizontal bone loss

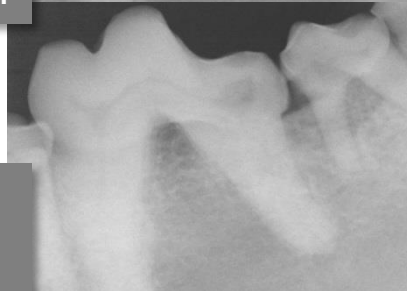Owner willing to brush for only 2 months....



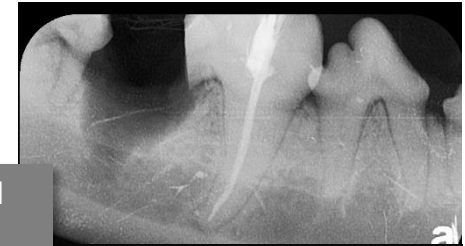2 months
Reconstruction of periodontium and restoration of crestal bone.



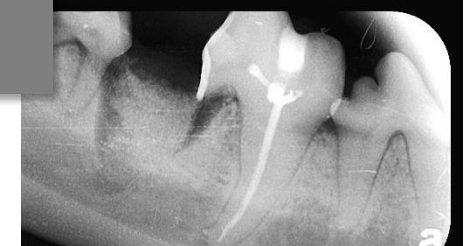32 months
Alveolar ridge height maintained long-term. Teeth have been preserved *without* brushing.



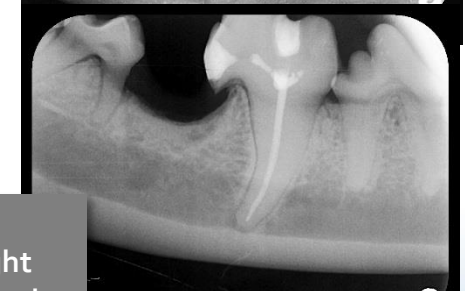Extraction plus Bioglass (Consil)



Hemi-section of distal root with root canal. Alveolus filled with Bioglass.



32 months
Alveolar ridge height lost long-term. Apical defect still visible.



Grafting with Allograft Can Preserve Teeth